

Perioperative Breast Analgesia

A Qualitative Review of Anatomy and Regional Techniques

Glenn E. Woodworth, MD,* Ryan M.J. Ivie, MD,* Sylvia M. Nelson, PhD,*
Cameron M. Walker, PhD,* and Robert B. Maniker, MD†

Abstract: Breast surgery is exceedingly common and may result in significant acute as well as chronic pain. Numerous options exist for the control of perioperative breast pain, including several newly described regional anesthesia techniques, but anesthesiologists have an insufficient understanding of the anatomy of the breast, the anatomic structures disrupted by the various breast surgeries, and the theoretical and experimental evidence supporting the use of the various analgesic options. In this article, we review the anatomy of the breast, common breast surgeries and their potential anatomic sources of pain, and analgesic techniques for managing perioperative pain. We performed a systematic review of the evidence for these analgesic techniques, including intercostal block, epidural administration, paravertebral block, brachial plexus block, and novel peripheral nerve blocks.

(*Reg Anesth Pain Med* 2017;42: 609–631)

Surgeries of the breast are among the most common operative procedures, and numerous options exist for perioperative anesthesia and analgesia that can affect acute perioperative pain, persistent pain, and potentially cancer recurrence. Patients who undergo breast surgery experience significant acute pain, but are also at risk of chronic pain. Up to 55% of postmastectomy patients experience chronic pain persisting for months to years.^{1–5} One of the best predictors of chronic pain following breast surgery is the amount of perioperative pain experienced by the patient.^{6–12} Although multiple options exist for control of perioperative breast surgery pain, including several newly described regional anesthesia techniques, there is insufficient understanding of the anatomy of the breast, the anatomic structures disrupted by the various breast surgeries, and the theoretical and experimental evidence supporting the use of the various analgesic options. In part I of this article, we review the anatomy of the breast and common breast surgeries, along with the potential anatomic sources of perioperative pain. We conclude with a discussion of the anatomic basis for different analgesic techniques. In part II, we present a systematic review of the evidence for the analgesic techniques including multimodal analgesia, local anesthetic infiltration, intercostal block, epidural administration, paravertebral block (PVB), brachial plexus block, and novel peripheral nerve blocks.

METHODS

To determine the evidence base for perioperative breast analgesia techniques, we performed a literature search of the MEDLINE

From the *Department of Anesthesiology & Perioperative Medicine, Oregon Health and Science University, Portland, OR; and †Department of Anesthesiology, Columbia University, New York, NY.
Accepted for publication March 15, 2017.

Address correspondence to: Glenn E. Woodworth, MD, Department of Anesthesiology and Perioperative Medicine, Oregon Health & Science University, 3181 SW Sam Jackson Park Rd, Portland, OR 97239 (e-mail: woodworg@ohsu.edu).

The authors declare no conflict of interest.

This work was funded by the Department of Anesthesiology and Perioperative Medicine, Oregon Health and Science University, Portland, OR; and the Columbia University Department of Anesthesiology, New York, NY.

Copyright © 2017 by American Society of Regional Anesthesia and Pain Medicine
ISSN: 1098-7339

DOI: 10.1097/AAP.0000000000000641

database via PubMed on November 5, 2016. The search combined terms for breast surgery, anesthesia, and analgesia. The PubMed search terms were ((“Analgesics” [MeSH] OR “analgesics” [all fields] OR “Analgesia” [MeSH] OR “analgesia” [all fields] OR “Anesthesia, Conduction” [MeSH] OR “nerve block” [all fields] OR “regional anesthesia” [all fields] OR “epidural” [all fields] OR “spinal anesthesia” [all fields] OR “neuraxial” [all fields] OR “general anesthesia” [all fields] OR “anaesthesia” [all fields] OR “anesthesia” [all fields] OR (“local” [all fields] AND “infiltration” [all fields])) AND (“Mammoplasty” [MeSH] OR “Mastectomy” [MeSH] OR “mammoplasty” [all fields] OR “mastectomy” [all fields] OR “breast surgery” [all fields] OR “chest wall” [all fields] OR “axilla*” [all fields] OR “Breast Neoplasms/surgery” [MeSH] OR “breast cancer surgery” [all fields] OR “mammary” [all fields] OR “breast augmentation” [all fields] OR “axillary surgery” [all fields])). The search was not limited by date and excluded conference abstracts. The search was replicated in the EMBASE database for articles published in journals not indexed in MEDLINE.

Articles were included if they met the following inclusion criteria: (1) randomized controlled trial (RCT) design; (2) participants were humans at least 18 years of age undergoing elective surgery on the breast (not including biopsy); (3) published in English and full text available; (4) analgesic interventions were intercostal block, interpleural block, epidural block, PVB, or novel peripheral nerve blocks; (5) outcome measures were postoperative analgesic consumption, postoperative pain scores, or duration of postoperative analgesia; and (6) minimum Jadad score of 2. Article titles and abstracts were screened, full-text articles were reviewed, and risk-of-bias assessments were performed by 2 authors independently (R.M.J.I. and R.B.M.), with any discrepancies resolved through discussion. Risk of bias was assessed using the 5-point scale described by Jadad et al.¹³ Articles using a study design other than RCT but meeting all other inclusion criteria were subsequently reviewed for findings not yet confirmed in RCTs.

The search strategy captured 5418 articles, of which 4407 were eliminated for failure to meet the inclusion criteria based on their titles and abstracts. Full-text review of the remaining 1011 articles eliminated an additional 965 articles that failed to meet the inclusion criteria, yielding a total of 46 articles (Fig. 1). Articles were organized according to intervention: 5 intercostal block, 0 interpleural block, 5 epidural block, 31 PVB, 1 brachial plexus block, and 4 novel peripheral nerve block.

DISCUSSION

Part I: Anatomy of the Breast, Surgical Disruption, and the Anatomic Basis for Regional Analgesia Techniques

Innervation of the Breast and Superficial Tissues

Several distinct nerves innervate the breast and surrounding tissues. The majority of the cutaneous sensation to the breast is derived from the intercostal nerves. Upon exiting the intervertebral foramina, the thoracic spinal nerves divide into dorsal and ventral rami. The dorsal rami innervate the skin and muscles over the

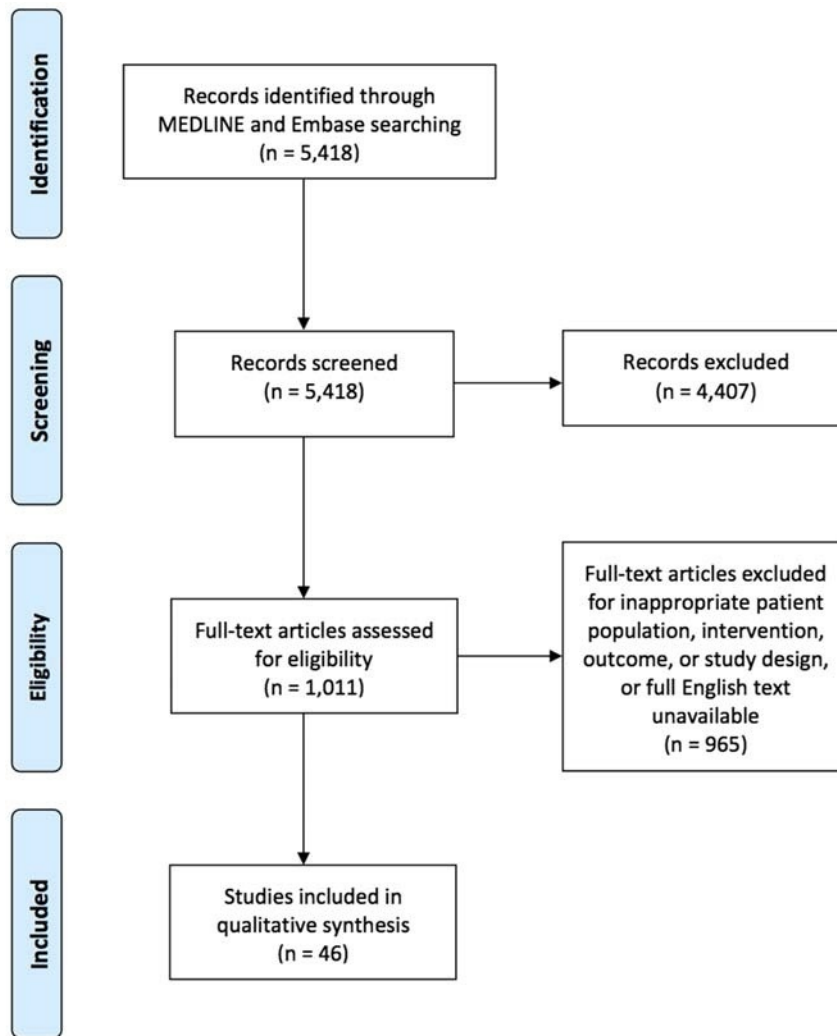


FIGURE 1. Flowchart of identified, screened, excluded, and analyzed studies.

medial back (Fig. 2). The ventral rami pass through the paravertebral space and become the intercostal nerves, which travel in the intercostal space just below the inferior border of the superior rib and are accompanied by an intercostal vein and artery. Much like the abdominal musculature, the intercostal region is composed of 3 muscle planes.¹⁴ From superficial to deep, the muscular planes are formed by the external intercostal muscle, the internal or intermediate intercostal muscle, and an innermost layer composed of the subcostal (posterior), innermost intercostal, and transversus thoracis (anterior) muscles. The intercostal nerves travel in the plane between the innermost layer and the internal intercostal muscle (Fig. 2).¹⁵ Near the midpoint between the spine and sternum, at approximately the angle of the rib and midaxillary line, a lateral cutaneous branch arises from the intercostal nerve and pierces the internal intercostal, external intercostal, and serratus anterior muscles (SAMs).¹⁵ The lateral cutaneous branches then divide into anterior and posterior divisions that provide cutaneous innervation to the lateral chest (Figs. 2–4). The continuation of the intercostal nerve terminates as an anterior cutaneous branch (ACB) by piercing the fascial extension of the external intercostal muscle close to the lateral edge of the sternum, providing cutaneous innervation to the medial chest and sternum (Figs. 2–4).^{15–17} In many texts, the anterior

division of the lateral cutaneous branch is referred to as the anterior branch. We have used the term “anterior division” in order to avoid confusion with the terminal portion of the intercostal nerve, the ACB.

The breast is essentially a subcutaneous organ that receives innervation from anterior and lateral cutaneous branches of intercostal nerves, as well as supraclavicular nerves. Published descriptions of the specific nerves involved and their courses vary significantly, likely because of both anatomic variability and differences in research methodology. The most commonly described pattern of innervation of the medial breast is by the ACBs of the T1 through T5 intercostal nerves with variable involvement of T1 and T6 and innervation of the lateral breast by the lateral cutaneous branches of the T2 through T5 intercostal nerves with variable involvement of T1, T6, and T7 (Figs. 3, 4).^{16–20} The first intercostal nerve rarely gives off a lateral cutaneous branch. Both the lateral and anterior branches of different intercostal nerves frequently communicate with each other throughout their course, producing a variable pattern of innervation that does not adhere to strict dermatomal segmentation.

The relationship of the cutaneous nerves of the breast to the underlying muscles is important as surgeons must avoid these nerves, and anesthesiologists seek to block them. After piercing

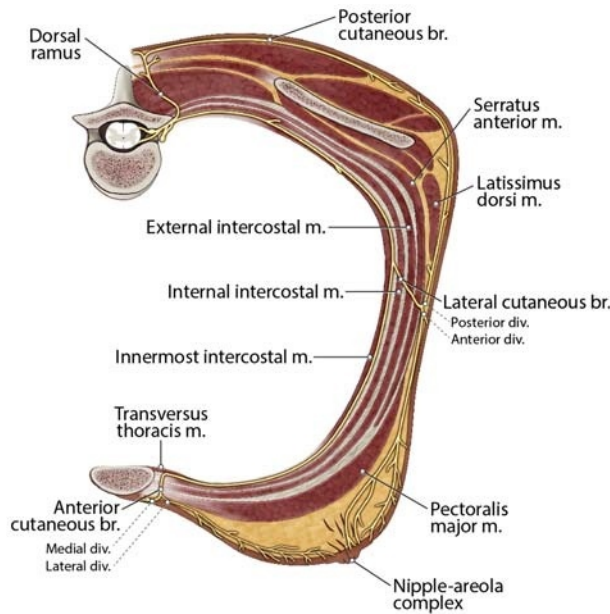


FIGURE 2. Course of the intercostal nerves. The ventral rami of the thoracic spinal nerves form the intercostal nerves, which travel in the intercostal space just below the inferior border of the superior rib. The intercostal region is composed of 3 muscle planes. From superficial to deep, the muscular planes are formed by the external intercostal, the internal or intermediate intercostal muscle, and an innermost layer composed of the subcostal, innermost intercostal, and transversus thoracis muscles. The intercostal nerves travel in the plane between the innermost layer and the internal intercostal muscle. Near the midpoint between the spine and sternum, a lateral cutaneous branch arises from each intercostal nerve and pierces the internal intercostal, external intercostal, and SAMs. The lateral cutaneous branches then divide into anterior and posterior divisions that provide cutaneous innervation to the lateral chest. The continuation of each intercostal nerve terminates as an ACB by piercing the fascial extension of the external intercostal muscle close to the lateral edge of the sternum, providing cutaneous innervation to the medial chest and sternum. Br indicates branch; div, division; m, muscle.

the internal and external intercostal muscles, the lateral cutaneous branches of the intercostal nerves penetrate through the slips of origin of the SAM. The anterior divisions of these nerves course over the lateral edge of the pectoralis major (PM) muscle to reach the cutaneous tissue of the chest (Figs. 3, 4). The T4 and T5 lateral cutaneous branches may also give rise to a deep branch that pierces the PM muscle before reaching the breast.¹⁷

The nipple-areola complex (NAC) is innervated by both anterior and lateral branches of the intercostal nerves T3 through T4, with variable contribution from T2 and T5. The exact innervation of the NAC is still controversial because of numerous anatomic variations and the difficulty in dissecting this area.²¹ The most common descriptions of NAC innervation detail a comingling of the terminal branches of the anterior divisions of the lateral cutaneous branches of the T4 and T5 intercostal nerves and the terminal branches of the ACBs.^{17-19,22}

Special consideration should be given to the course of the lateral cutaneous branch arising from the T2 intercostal nerve, termed the *intercostobrachial nerve*. As with the other lateral cutaneous branches, this nerve branches off the intercostal nerve around the angle of the rib. The lateral aspect of the T2 rib lies in the axilla. After piercing the intercostal and SAMs, the majority

of the lateral cutaneous branch of T2 travels laterally along the floor of the base of the axilla to reach the upper medial arm (Fig. 5). The intercostobrachial nerve provides cutaneous innervation to the axillary tail of the breast, the axilla, and the medial upper arm. The extrathoracic anatomy of this nerve is highly variable. It may receive contributions from other intercostal branches (T1, T3, and even T4) and can have a variety of anastomoses with branches of the brachial plexus, including the medial antebrachial cutaneous nerve, posterior cutaneous nerve of the forearm, and rarely with the pectoral nerves.²³⁻²⁵ This nerve is often implicated in postmastectomy pain, particularly after axillary dissection or lymph node sampling.^{26,27} Its variable anatomy may account for the conflicting reports of post-nerve injury symptoms.

In addition to the innervation of the breast tissue and skin from the intercostal nerves, a small portion of the superior breast skin may be innervated by the supraclavicular nerves, although this description has been disputed.^{16,17,28} These nerves originate from the superficial cervical plexus and eventually travel in the subcutaneous tissue to pass over the clavicle and reach the superior aspect of the breast (Figs. 3, 4).

Innervation of the Chest Wall

Although the cutaneous innervation of the breast is derived from the intercostal nerves with a small contribution from the supraclavicular nerves, the brachial plexus supplies the innervation to the muscles of the chest wall (other than the intercostal muscles, which derive their innervation from the intercostal nerves). The majority of the breast tissue is immediately anterior to the pectoralis muscles. The upper portion of the PM muscle is supplied by the lateral pectoral nerve (LPN), whereas the medial pectoral nerve (MPN) innervates the pectoralis minor (Pm) muscle and the lower portion of PM.^{29,30} These nerves arise from the brachial plexus at variable locations and take a variable course

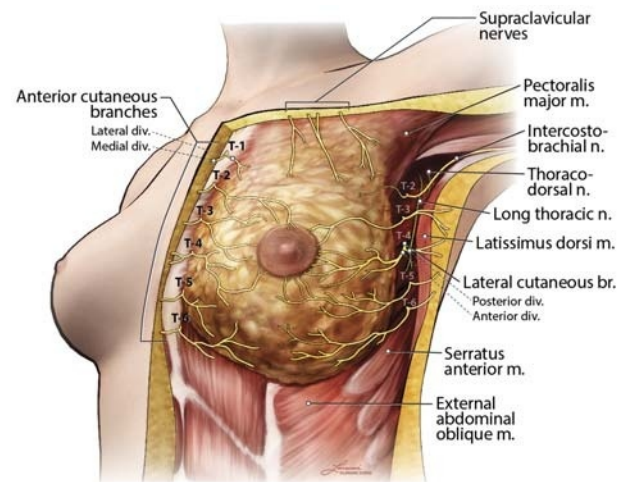


FIGURE 3. Innervation of the breast. Medially, the ACBs of the intercostal nerves can be seen piercing the PM near the sternum to innervate the medial breast. The supraclavicular nerves cross the clavicle and innervate the skin inferior to the clavicle and potentially a portion of the superior pole of the breast. The lateral cutaneous branches of the intercostal nerves divide into anterior and posterior divisions, which pierce the SAM. The anterior divisions provide innervation to the lateral breast. Also depicted are the posterior divisions, which can be seen entering the subcutaneous tissue to innervate the lateral chest wall. The lateral cutaneous branch of T2 forms the intercostobrachial nerve, which innervates the axilla and the medial upper arm. Br indicates branch; div, division; m, muscle; n, nerve.

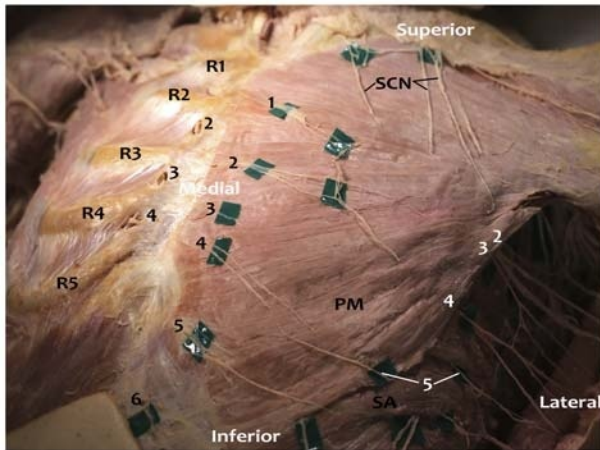


FIGURE 4. Photograph of anterior body wall nerves. The breast and subcutaneous tissue has been removed from this female donor, while preserving the nerves. Anterior cutaneous branches (black numbers) of the intercostal nerves emerge from the intercostal spaces and travel inferolaterally before piercing the PM muscle. On the donor right, the PM has been reflected. The ACBs on the donor right are visible exiting inferior to the rib through the internal intercostal muscle and external intercostal fascia, which has been partially removed to demonstrate the nerve exit point. This exit point is slightly superior to the ACBs exiting through the PM on the donor left. Fine branches of the ACBs were once connected to each other, to the supraclavicular nerves, and to the anterior divisions of lateral cutaneous branches. The supraclavicular nerves can be seen traveling caudally to innervate the superior chest. These nerves may reach the superior pole of the breast tissue, which overlies the second or third rib. On the lateral chest wall, the divisions of the lateral cutaneous branches (LCB, white numbers) of the intercostal nerves can be seen piercing the SAM. The anterior division of the fifth LCB is visible, whereas other anterior divisions entering the lateral breast were lost during removal of the breast tissue. The nerves that can be seen extending laterally are the posterior divisions. In this dissection, we noted the anterior and posterior divisions of the fifth LCB exited through the serratus anterior at different locations. R1–R5 indicates first to fifth ribs; SA, serratus anterior; SCN, supraclavicular nerves.

to the pectoralis muscles (Fig. 6). The LPN is derived from the C5–7 nerve roots and arises most frequently from the anterior division of the upper trunk of the brachial plexus or from the lateral cord, from which it derives its name.³¹ The MPN is derived from the C7–T1 nerve roots and usually arises from the medial cord.

Both nerves depart the axilla to travel medially toward the pectoralis muscles.^{29,30,32–35} The LPN crosses the lateral and superior border of the Pm muscle to enter the plane between the PM and Pm muscles, usually alongside the pectoral artery (Figs. 6, 7).³⁶ This fascial plane and artery are often used as sonographic landmarks to locate the LPN. The LPN provides numerous branches that penetrate the deep surface of the PM muscle and supply the innervation to the superior and medial aspect of the muscle. The MPN usually travels deep (posterior) to the Pm muscle, supplying its innervation, before coursing anteriorly to supply innervation to the inferior portion of the PM. The MPN may pierce the Pm muscle or emerge from beneath the inferior edge of the muscle to reach the PM, or both (Figs. 6, 7). Although these nerves do not innervate the subcutaneous tissue of the breast, they still play an important role in breast surgical pain. Disruption, stretching, or spasm of the pectoral muscles or associated fascia can be a significant source of myofascial pain after breast

surgery.^{37,38} Although often labeled simply as motor nerves, they have been described to carry both nociceptive and proprioceptive fibers.³⁹ In addition to proprioception, all of the motor nerves to the chest wall carry postganglionic fibers from the cervical and thoracic ganglion, which may be another mechanism for communication of pain.⁴⁰ Aside from injury to the tissues supplied by the nerves, traction, radiation, or other direct nerve injury may play a role in postsurgical neuropathic pain.⁴⁰

Two other important nerves in the region of the axilla and lateral chest wall are the long thoracic and thoracodorsal nerves (TDNs), both of which originate from the brachial plexus. The long thoracic nerve (LTN) arises from the C5–7 nerve roots. Upon reaching the infraclavicular region, it runs along the lateral chest wall superficial to the SAM, which it innervates (Fig. 6). Disruption of the SAM during breast reconstruction (making a pocket for an implant) can result in myofascial pain to the chest wall radiating to the subscapular region.³⁸

The TDN is derived from the C6–8 nerve roots and arises from the posterior cord of the brachial plexus. It exits the posterior wall of the axilla to travel along the anterior and lateral portion of the latissimus dorsi muscle in close proximity to the subscapular artery, where it innervates the latissimus dorsi muscle (Figs. 6, 7).

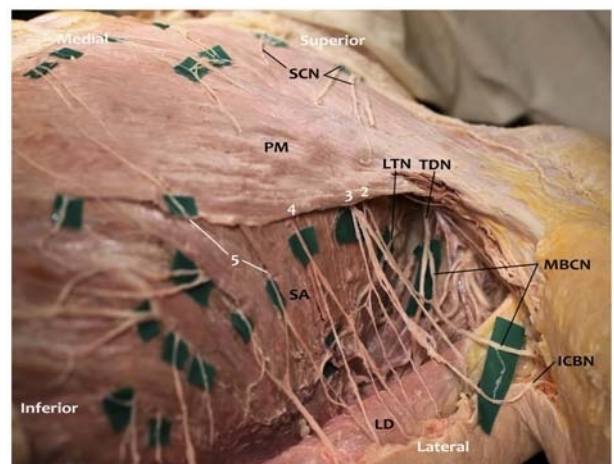


FIGURE 5. Photograph of left lateral chest wall and axilla with subcutaneous tissue removed. In this photograph, the subcutaneous tissue and breast have been removed, while preserving the nerves in this female cadaver. The dissection was extended to expose the axilla. Lateral cutaneous branches (LCB, white numbers) of the intercostal nerves emerge between the leaflets of the serratus anterior (SA) muscle. Most of the anterior divisions of the LCBs were removed along with the removal of the breast tissue. Posterior divisions of the LCBs travel posterolaterally to innervate the skin of the lateral body wall. In this specimen, the posterior division of the second LCB emerges deep to the PM and anastomoses with the third LCB to form the intercostobrachial nerve (ICBN). The posterior division of the second LCB also anastomoses with the medial brachial cutaneous nerve (MBCN) to innervate the axilla and upper arm. This is a common anatomical occurrence. Also shown are the TDN, which innervates latissimus dorsi (LD), and the LTN, which innervates the SA muscle. The anterior and posterior divisions of the fifth LCB emerge separately through the SA, with the anterior division coming around the lateral border of PM to innervate the breast. In this specimen, separate exit points of the divisions of the lateral cutaneous branches of the intercostal nerves through the serratus anterior were observed. The anterior divisions of the fourth and fifth LCBs (and likely the second and third) anastomosed with the ACBs of the intercostal nerves. Anastomoses with the supraclavicular nerves were also observed.

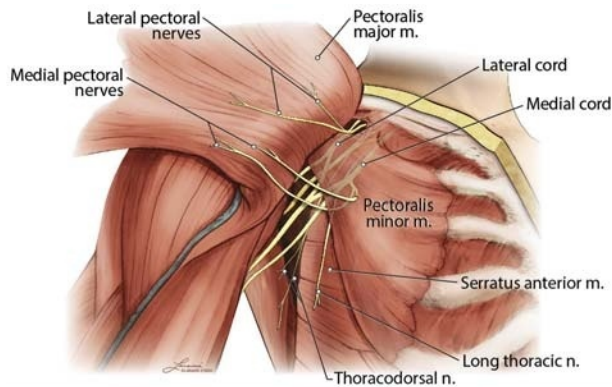


FIGURE 6. Diagram of pectoral nerves. In this diagram, the PM muscle was reflected laterally to demonstrate the pectoral nerves arising from the brachial plexus. The LPN is depicted arising from the lateral cord of the brachial plexus and innervates the PM. The MPN is shown arising from the medial cord. Some of the branches of the MPN pierce the Pm muscle, which it innervates, to reach the caudal aspect of the PM. Another branch of the medial pectoral nerve courses caudal to the edge of Pm to reach the PM. Both courses of the MPN branches are common. Also depicted is the LTN innervating the SAM and the TDN innervating the latissimus dorsi muscle. Both nerves arise from the brachial plexus. Not shown are the cutaneous branches of the intercostal nerves. N indicates nerve; m, muscle.

Similar to the LTN, injury to this nerve has been implicated in postmastectomy pain.^{38,40}

Breast Surgery and Tissue Disruption

Knowledge of the precise anatomic location of tissue disruption for each type of breast surgery is imperative in developing a perioperative analgesic plan. Operations involving the breast can differ substantially with regard to the tissues that are removed or compromised. Breast cancer procedures are discussed first.

Excisional Breast Surgery

Lumpectomy involves excision of a wedge of subcutaneous breast tissue. A partial (segmental or quadrantectomy) mastectomy is performed if more breast tissue warrants removal. This procedure is performed for tumors that are too large for lumpectomy, for patients who cannot tolerate radiation, or if more than 1 distinct area of the breast is involved. As with a lumpectomy, only subcutaneous breast tissue is removed.⁴¹ Depending on whether surgery is performed medial or lateral to the nipple, the anterior or lateral cutaneous branches of the intercostal nerves (respectively) will contribute to the innervation of the operative area. A total (simple) mastectomy involves removing the entire subcutaneous breast tissue and varying amounts of overlying skin. The underlying fascia of the PM muscle is not disrupted.⁴² Similar to lumpectomies and partial mastectomies, the intercostal nerves are responsible for the innervation to the surgical area. When developing a plan for perioperative analgesia, it is important to determine if an axillary dissection or sentinel node biopsy will be performed in conjunction with a partial or total mastectomy. Surgery in the axilla is in the territory of the intercostobrachial nerve (lateral cutaneous branch of T2), which may require separate blockade, depending on the chosen analgesic approach.

A radical mastectomy is a more extensive breast cancer operation involving removal of the entire breast, nipple, axillary lymph nodes, and pectoralis muscles. More commonly, a mastectomy and sentinel node biopsy are performed, or alternatively, a modified radical mastectomy, which includes a mastectomy and an

axillary dissection but preserves the pectoralis muscles, is performed.⁴³ The borders of dissection extend superiorly to the clavicle, medially to the sternum, inferiorly to the most caudal extent of breast tissue (on the costal margin below the inframammary fold), and laterally in the axilla to the border of the latissimus dorsi. The fascia of the PM muscle forms the deep margin of the dissection and is removed during the procedure, which may constitute a source of postoperative myofascial pain.⁴⁴ The dissection also frequently involves removal of breast tissue or lymph nodes that reside between the inferior edge of the PM muscle and the Pm muscle. This is important as the MPN can be injured, resulting in partial denervation of the PM muscle.^{32,33} In addition, manipulation and stretching of the pectoralis muscles may be another source of perioperative myofascial pain. One or 2 drains may be placed through separate inferior-lateral incisions and can be additional sources of pain below the dermatomes associated with the breast. Mastectomy requires general anesthesia or an advanced regional block with sedation. In contrast to pain from simple mastectomy, brachial plexus–derived nerves (lateral and medial pectoral, thoracodorsal, long thoracic) can also contribute to perioperative modified radical mastectomy pain (Fig. 7).

Reconstructive Breast Surgery

Because of the disfiguring nature of breast cancer surgery, surgical reconstruction to restore a natural breast appearance is frequently performed in conjunction with breast cancer procedures.⁴⁵ In reconstructions with an implant, a tissue expander is usually placed beneath the PM muscle and anterior to the Pm. Laterally, the SAM may be elevated to cover the inferolateral pole of the implant.⁴⁶ The inflatable bladder is expanded over days to weeks to slowly stretch the overlying PM muscle, fascia, and skin. In a second operation, the temporary expander is replaced by a long-term implant. It is important to identify whether a tissue expander will be placed after a total mastectomy. Unlike total mastectomy without a tissue expander, this procedure will involve blunt dissection of a pocket for the expander between the pectoral muscles. Creation of the pocket can be a source of additional perioperative and chronic pain due to direct disruption of the pectoral nerves or lateral cutaneous branches of the intercostal nerves

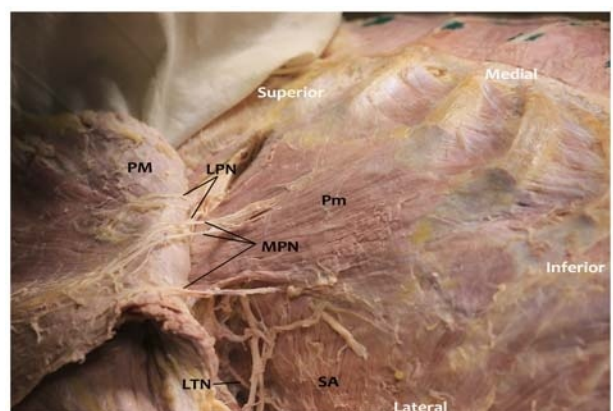


FIGURE 7. Photograph of pectoral nerves. In this photograph, the subcutaneous tissue and breast have been removed, while preserving the nerves in this female cadaver. The PM muscle is reflected laterally to show branches of the LPN on its deep surface. Two branches of the MPN pierce the Pm muscle to innervate the inferior third of PM, and 1 branch of the MPN circumscribes the lateral border of the Pm (accompanied by an artery and vein) to innervate the most inferior fibers of the PM. Posteriorly, the LTN is demonstrated innervating the SA muscle.

or due to stretching or injury to the fascia of the serratus anterior or pectoral muscles. Women who undergo breast cancer surgery with immediate reconstruction have a higher prevalence of chronic pain when compared with women who undergo mastectomy without reconstruction (49% and 31%, respectively).¹² An important consideration in developing a perioperative analgesic plan for breast surgery with reconstruction is the involvement of not only the intercostal nerves, but also the pectoral nerves and possibly the LTN (Fig. 7).

With implant reconstruction, a sheet of mesh or acellular dermal matrix is often used to provide internal support to the implant and to extend the lower border of the PM muscle. This allows the muscle to be held in place against the chest wall at the desired inframammary fold and provides an additional source of coverage material for the lower pole of the implant. This material is sewn directly to the chest wall, with sutures placed in rib periosteum or deep chest wall fascia, often creating a significant source of postoperative discomfort. Analgesia is targeted to the level of the sixth and seventh intercostal spaces (at the level of the inframammary fold) to address pain from these sutures.

Another type of reconstruction, either delayed or immediate, involves a free or pedicle flap to recreate breast volume.⁴⁵ The most common procedures include transverse rectus abdominis myocutaneous flaps, either performed as a pedicled or free flap; deep inferior epigastric artery perforator as a free flap; and latissimus dorsi myocutaneous flaps as a pedicled flap. When developing a perioperative analgesic plan, the donor site for the flap must be considered in addition to the breast surgery itself. For example, a patient undergoing total mastectomy with immediate pedicled transverse rectus abdominis myocutaneous flap reconstruction may experience more postoperative pain from the abdominal wall donor site than from the mastectomy site.^{47,48} This is due to the resection of the rectus muscle and closure of the rectus sheath (primarily or with synthetic mesh).

When a traditional latissimus dorsi flap is used for breast reconstruction, an ellipse of skin is harvested from the back over the lower thoracic region to act as the donor site. The entire latissimus muscle is then elevated from a pocket that extends subcutaneously from the mid-lumbar region inferiorly to the tip of the scapula superiorly and from the paraspinous muscle fascia medially to the posterior axillary line laterally. The flap is passed through a tunnel near the axilla to the anterior chest. Any indwelling anesthetic catheter would need to cover the entire hemiback to the posterior midline on the side of the flap. It is also important to note that this muscle is innervated by the TDN, a branch of the brachial plexus.

Breast Augmentation

Mammoplasty refers to a group of procedures aimed at changing the shape and/or size of the breast, typically by augmentation or reduction. In primary breast augmentation, implants are generally placed via 1 of 4 skin incisions: periareolar, inframammary, transaxillary, or less commonly transumbilical. The transaxillary approach requires special consideration because of possible injury to the intercostobrachial nerve in the axilla, which may result in acute and chronic axillary pain.⁴⁹ The implant is generally placed in 1 of 2 pockets—behind the breast parenchyma and superficial to the PM muscle, or deep to the PM muscle. As with tissue expanders, creation of a pocket posterior to the PM muscle can be a source of postoperative myofascial pain. The dissection required for the pocket involves disruption of the PM muscle and its attachments to the cartilaginous portion of the ribs. In some cases, the muscle fibers of the PM are split to access the plane posterior to the PM and anterior to the Pm muscle. Unlike tissue expander placement, the implant will usually be placed at its final size and not inflated over time. In addition to direct manipulation

and disruption to the muscles and fascia, the stretch of the PM muscle after implant placement can be substantial. The major source of pain from submuscular breast augmentation is myofascial and is transmitted by the pectoral nerves. Postoperative pain from the stretching and disruption of the pectoral muscles is common, and many surgeons prescribe muscle relaxants to ameliorate it.⁵⁰ Creation of the submuscular pocket may also directly disrupt the pectoral nerves and/or the lateral cutaneous branches of the intercostal nerves. As with breast cancer surgery, breast augmentation procedures can lead to persistent pain. In one study, 9.5% of patients reported moderate to severe persistent pain after submuscular breast augmentation, 75% reported sensory changes over the breast, and 38% met criteria for neuropathic pain.⁵¹

Other Cosmetic Breast Surgeries

Two additional procedures to be considered are reduction mammoplasty and mastopexy. In these procedures, a volume of breast tissue is removed, while the areola and nipple are spared. From a perioperative analgesic standpoint, these procedures are similar to a simple mastectomy because only cutaneous and subcutaneous breast tissue is involved, and the pectoral muscles are not disrupted. The incisions vary but typically involve the periareolar region and inferior pole of the breast.

The various surgical procedures and the relevant innervation are summarized in Figure 8.

Anatomic Basis of Analgesic Procedures

The goals of perioperative analgesia are to provide or supplement operative anesthesia, reduce immediate postoperative pain, and reduce the incidence of chronic pain. Regional anesthesia modalities have gained popularity for breast surgery due to the recent focus on reducing the requirement for inpatient surgery, inpatient length of stay, and the incidence of persistent postsurgical pain. We now discuss the anatomic basis of various procedures for the control of perioperative breast pain, as summarized in Figure 8. A discussion of how to perform the various blocks is beyond the scope of this review.

Intercostal Nerve Blocks

Local anesthetic can be deposited near intercostal nerves to provide a band of anesthesia targeted to a specific dermatomal area. Multiple intercostal nerves must be blocked to achieve coverage for breast surgery, depending on the tissue disrupted (eg, T2–T7). Classically, 3 to 5 mL of local anesthetic solution is injected at each thoracic level.⁵² If only the medial breast is involved, intercostal blocks may be performed at any point along the intercostal nerve course, including at the exit point of the ACB just medial to the sternum. If the lateral breast is involved, intercostal blocks must be performed proximal to the origin of the lateral cutaneous branches of the intercostal nerves at the midaxillary line. Intercostal blocks should be combined with other approaches if the surgery involves myofascial pain, as thoracic intercostal blocks do not anesthetize nerves derived from the brachial or cervical plexuses.

Thoracic Epidural

The most common levels for placement of epidural injections or catheters for breast analgesia is T3–5. Similar to intercostal blocks, thoracic epidural anesthesia (TEA) without cervical spread would not block the branches of the brachial or cervical plexus that may contribute to perioperative breast surgery pain.

Paravertebral Block

The paravertebral space can be accessed to block the thoracic spinal nerves as they exit the intervertebral foramina. Local anesthetic deposited in this space can spread multiple levels superior

Cutaneous and Subcutaneous Innervation				Muscle Innervation (Myofascial Pain)				
Nerves	Intercostal nerves			Cervical plexus	Brachial plexus			
	Intercostobrachial nerve (T2)	Lateral cutaneous branches	Anterior cutaneous branches	Supraclavicular nerves	Lateral pectoral nerve (C5-7)	Medial pectoral nerve (C7-T1)	Thoracodorsal nerve (C6-8)	Long thoracic nerve (C5-7)
Supply	Axilla & Medial upper arm	Lateral half of breast	Medial half of breast	Cranial portion of the breast	Pectoralis major	Pectoralis minor & major (caudal portion)	Latissimus dorsi	Serratus anterior
Surgical Procedures	if sentinel lymph node biopsy		Lumpectomy					
			Partial and total mastectomy					
			Subglandular augmentation					
			Mastopexy and reduction mammoplasty					
	if axillary lymph node dissection		Modified radical mastectomy				if axillary lymph node dissection	
	Submuscular augmentation or tissue expander						Latissimus dorsi flap	Submusc aug / TE
Analgesic Procedures	Local anesthetic infiltration							
	Intercostal nerve blocks							
	Epidural analgesia							
	Paravertebral block							
				Interscalene block		partial block		Interscalene block
	Infraclavicular block			Infraclavicular block ^a				
	Pecs I block			Pecs I block				
	Pecs II block			Pecs II block ^b				
	Serratus plane block			Serratus plane block				
	Anterior cutaneous branch blocks							

FIGURE 8. Summary of chest wall innervation, breast surgeries, and analgesic procedures. The innervation of the chest wall is summarized, along with the various breast surgeries organized by the corresponding nerves involved. The regional analgesic procedures and the nerves anesthetized by each approach are depicted. ^aInfraclavicular block may also anesthetize the LTN and lateral cutaneous branches of the intercostal nerves through spread along the lateral chest wall. As the extent and frequency of this spread remain unproven, block of these nerves is not depicted. ^bPecs II block may spare the LTN when using the modified technique of injecting local anesthetic deep to the SAM. TE indicates tissue expander.

and/or inferior, as well as into the intercostal space laterally, the contralateral paravertebral space, and the epidural space medially.⁵³ This technique generally results in ipsilateral blockade of somatic and sympathetic nerves and can serve as the sole anesthetic for breast surgery, as long as blockade of the supraclavicular nerves, pectoral nerves, or other brachial plexus branches is not required (similar to TEA).

Brachial Plexus and Novel Peripheral Nerve Blocks

Alternative regional techniques have been proposed in an effort to provide equivalent or improved analgesia with a lower risk of adverse events and greater suitability for outpatient surgery (see part II for the evidence base behind claims of efficacy and safety for each technique). Initial efforts were aimed at blocking some or all of the peripheral nerves of brachial plexus origin that provide sensory innervation to the breast: LPN, MPN, LTN, and TDN. Subsequent efforts have aimed to expand the utility of these novel blocks by simultaneously anesthetizing the cutaneous branches of the intercostal nerves.

Brachial plexus blocks. The LPN, MPN, and TDN typically arise from the anterior division of the upper trunk or lateral cord, medial cord, and posterior cord, respectively. Thus, infraclavicular brachial plexus block at the level of the cords would be expected to block these brachial plexus components of breast analgesia, and possibly the LTN as it courses along the lateral chest wall. In contrast, interscalene block at the level of the C5–7 nerve roots would be expected to block the LTN, but only partial blockade of the LPN, MPN, and TDN because of absence of reliable C8 and T1 nerve root block. It is important to note that interscalene block is not expected to provide axillary analgesia, because sensory innervation of the axilla is derived primarily from the intercostobrachial nerve (T2 intercostal nerve). Because of its proximity to the axilla, infraclavicular block typically does result in block of the

intercostobrachial nerve and axilla. Bigeleisen and Wilson⁵⁴ demonstrated 77% and 87% incidence of intercostobrachial nerve block with 10 mL volume infraclavicular block via a medial and lateral approach, respectively. Although anatomically possible, the extent to which infraclavicular block provides local anesthetic spread along the chest wall to anesthetize the lateral cutaneous branches of the intercostal nerves other than the intercostobrachial nerve, and thus provide breast analgesia, has not been adequately studied. With the possible exception of infraclavicular blocks, brachial plexus blocks alone will not anesthetize the thoracic intercostal nerves supplying the breast and would not be sufficient for complete breast analgesia.

Pecs I block. Novel blocks have recently been introduced in an effort to anesthetize key nerves derived from the brachial plexus, avoid blocking the brachial plexus nerves that innervate the arm, and block the cutaneous branches of the intercostal nerves. Blanco⁵⁵ was the first to describe a novel ultrasound-guided interfascial plane block, the Pecs I block, targeting the LPN and MPN via an injection between the PM and Pm muscles (eg, 0.25% bupivacaine 0.4 mL/kg). Distribution of local anesthetic in this plane is expected to anesthetize the LPN as it courses between the PM and Pm muscles and the MPN as it courses anteriorly through or at the lateral margin of the Pm muscle, with the goal of reducing postoperative muscle spasm and myofascial pain from the pectoralis muscles (eg, surgeries involving the pectoral muscles, including tissue expander and subpectoral prostheses placement).⁵⁵ Note that evidence is needed to support this theoretical mechanism of chest wall analgesia (see part II).

Pecs II block. In order to expand the utility of interfascial peripheral nerve blocks for breast surgery, Blanco et al⁵⁶ proposed a modification of the Pecs I block, called the Pecs II block. This block is performed with ultrasound guidance at the level of ribs

2–4. Pecs II block consists of 2 injections, one deep injection between the Pm muscle and the SAM with 20 mL bupivacaine 0.25% and one superficial injection identical to the Pecs I block (between the PM and Pm muscles) with 10 mL bupivacaine 0.25%. Both injections can be made via one skin puncture site and often via 1 needle pass. The terminology of this block (named the Pecs II block or modified Pecs I block by Blanco) has led to some confusion as some authors have erroneously used “Pecs II” to describe the deep injection alone.

The addition of the deep injection (between the Pm muscle and the SAM) targets 3 distinct nerve groups: the anterior divisions of the lateral cutaneous branches of the intercostal nerves that pierce the external intercostal muscle and SAM at approximately the midaxillary line, the LTN that courses along the superficial surface of the SAM, and the TDN that courses along the deep surface of the latissimus dorsi muscle. Of note, in an effort to improve interfascial spread and spare the LTN, Pérez et al⁵⁷ proposed a modification of the Pecs II block, wherein the deep injection is performed deep to the SAM rather than superficial to the SAM. Sparing of the LTN would allow for postoperative assessment given the risk of surgical injury to this nerve during axillary dissection.⁵⁷

The ACBs of the intercostal nerves (terminal portion of the intercostal nerves exiting near the sternum) would not be expected to be anesthetized with a Pecs II block unless local anesthetic were to diffuse deep to the SAM and the external and internal intercostal muscles to reach the intercostal nerve. Thus, a Pecs II block alone would be expected to leave sensory innervation of the medial breast intact.

Serratus plane block. Blanco et al⁵⁸ described another variation of the Pecs blocks, termed the *serratus plane block* (SPB), with the goal of providing extended intercostal nerve coverage. This block is performed more distal and lateral than Pecs II block, overlying the fifth rib at the midaxillary line. The latissimus dorsi muscle is visualized with ultrasound overlying the SAM. Identification of the thoracodorsal artery can verify the plane between the 2 muscles. Local anesthetic (eg, bupivacaine 0.125% 0.4 mL/kg) can be deposited either superficial or deep to the SAM, in an attempt to provide sensory block of the T2–T9 dermatomes.⁵⁸

De la Torre et al⁵⁹ and Alfaro-de la Torre and Fajardo-Pérez⁶⁰ have developed a nearly identical block termed the *serratus-intercostal fascial block* that involves deposition of local anesthetic deep to the SAM, between the SAM and external intercostal muscle. It is important to understand that SPB replaces only the deep injection of Pecs II block (between the Pm muscle and SAM), necessitating addition of a Pecs I block to cover the LPN (eg, for subpectoral device implantation).⁵⁷

Similar to the Pecs II block, the SPB likely blocks only the lateral cutaneous branches of the intercostal nerves, thus failing to anesthetize the medial breast. It is unclear if the local anesthetic diffuses through the SAM and external intercostal and internal intercostal muscles to reach the intercostal nerve proximal to the origin of the lateral cutaneous branch. Closer proximity to the intercostal nerves is one of the theoretical advantages of injection deep to the SAM, but this remains insufficiently studied.

Blocks of the ACBs of the intercostal nerves. In order to target the ACBs of the intercostal nerves, de la Torre et al⁵⁹ described the pectorintercostal fascial block (PIFB). This ultrasound-guided block is performed at the medial aspect of the breast, 2 to 3 cm lateral to the sternal border at the level of the fourth rib. The PM muscle is visualized superficial to the external intercostal muscle, and local anesthetic is deposited between these 2 muscles.

In a similar approach, Ueshima and Kitamura⁶¹ described the transversus thoracis muscle plane (TTP) block. This block is performed in the parasternal location; however, the local

anesthetic is deposited in a deeper interfascial plane between the transversus thoracis muscle (deep) and the internal intercostal muscle (superficial).⁶¹ Potential anatomic disadvantages of this approach are the very close proximity to the pleura (because TTP is very thin)¹⁵ and the internal thoracic artery (because it travels in the same plane between the transverse thoracis muscle and the internal intercostal muscle approximately 1 cm lateral to the sternum).⁶² The extent of local anesthetic spread and subsequent analgesia following PIFB and TTP block require further study.

It is important to recognize the anatomic limitations of the individual interfascial approaches. None of these approaches are expected to block the supraclavicular nerves that may supply a small portion of the superior breast.⁶³ Only the PIFB and TTP block anesthetize the ACBs of the intercostal nerves that supply the medial aspect of the breast. Thus, combinations of blocks are necessary to provide complete analgesia for many surgical procedures.⁵⁹

With a sophisticated understanding of the anatomy relevant to breast surgery and analgesia, combinations of various blocks will likely provide postoperative analgesia and even surgical anesthesia for a wide variety of operations (Fig. 8). Before adopting these promising blocks, a review of the evidence for their efficacy and safety is warranted.

Part II: Systematic Review of the Evidence for Regional Analgesia Techniques for Breast Surgery

Intercostal Nerve Blocks

Five studies evaluating intercostal nerve block with a median Jadad score of only 2 (range, 2–3) were included in the review. Of these 5 studies, 3 demonstrated improved analgesia in patients receiving intercostal blocks (Table 1).^{64–66} The role of intercostal nerve blocks in contemporary practice is questionable, given the mixed results, the risks associated with these multilevel blocks, and the presence of alternative peripheral approaches including local anesthetic infiltration and the novel interfascial peripheral nerve blocks. High-quality studies to directly compare intercostal nerve blocks to these alternative techniques, with attention to both analgesic benefit and adverse effects, are needed to clarify the utility of intercostal blocks for patients undergoing breast surgery.

Epidural Administration

Five studies evaluating TEA with a median Jadad score of 3 were included in the review. Of these 5 studies, 2 studies^{71,72} utilized continuous postoperative local anesthetic infusion, 2 studies^{69,70} utilized epidural anesthesia in the operating room only, and 1 study⁶⁸ utilized epidural morphine alone (Table 2). Three studies^{69,70,72} demonstrated effective surgical anesthesia with epidural block for modified radical mastectomy or mastectomy. All 5 studies demonstrated analgesic benefit with an epidural technique, although only 2 utilized a double-blind design. In the studies utilizing continuous postoperative epidural infusion, analgesic benefit persisted until epidural discontinuation (second postoperative day).^{71,72} In addition to reductions in pain scores and analgesic consumption, epidural anesthesia resulted in shorter hospital stay,⁷¹ faster achievement of postanesthesia care unit discharge readiness,⁷² and improved patient satisfaction.^{69,70,72} Although the evidence supports the ability of epidural technique to provide both surgical anesthesia and postoperative analgesia, concerns regarding adverse events and logistic constraints have prevented this technique from becoming common practice for breast surgery.

TABLE 1. Randomized Controlled Trials on Intercostal Block for Breast Surgery

Reference	Year	n*	Jadad Score	Type of Surgery	Details of Intervention	Control	Relevant Outcomes†	Acute Analgesia Results	Additional Findings
Atanassoff et al ⁶⁴	1991	30/15	2	Lumpectomy	T3–T7, preop, blind, surgical block with lidocaine 2% (plus epinephrine or ornipressin) 5 mL per level, intraop sedation (no GA)	GA	Need for postop analgesic medication‡	Less analgesic medication usage in block group	Less PONV in LA group
Atanassoff et al ⁶⁵	1994	36/12	2	Lumpectomy	T3–T6, preop, blind, surgical block with lidocaine 1.5% plus epi, lidocaine 2% plus epi, or bupivacaine 0.5%, 4 mL per level, intraop sedation (no GA)	GA	Pain VAS every 10 min for first 90 min; analgesic consumption in first 24 h‡	Lower pain scores during first 90 min, less analgesic consumption in first 24 h in block group	Longer analgesic effect with bupivacaine
Fassoulaki et al ⁶⁶	2001	47/49	3	Modified radical mastectomy, lumpectomy with ALND	T3–T5, intraop, blind, ropivacaine 1% 2 mL per level plus 12 mL brachial plexus infiltration (18 mL total)	Saline infiltration	Pain VAS at 0, 3, 6, 9, 24 h, POD 2–6 at rest and movement; IM analgesic consumption in first 24 h; PO analgesic consumption POD 2–5	Lower pain scores at 3 h only, less IM analgesic consumption at 24 h, no difference in PO analgesic consumption	No difference in pain at 3 mo
Hidalgo and Pusic ⁵⁰	2005	50/50	3	Augmentation (subpectoral; transaxillary, periareolar, or inframammary)	T2–T6, bilateral, preop, postinduction, bupivacaine 0.25% 40 mL total	No block	Pain VAS at 1, 3, 6, 24, 48, 72 h; postop narcotic consumption at 1, 3, 6 h	No difference in pain scores or postop narcotic consumption	Patients receiving methocarbamol (half of each group) had lower pain scores at 1 h only and no difference in narcotic consumption
Nasr et al ⁶⁷	2015	13/13	2	Augmentation (subpectoral, periareolar)	T2–T7, unilateral, preop, bupivacaine 0.25% with epi 3 mL per level, plus Pm infiltration with bupivacaine 0.25% 2 mL	Contralateral intraop PM muscle infiltration with bupivacaine 0.25% with epi	Pain VAS at 0, 1, 3, 8, 24 h at rest and movement	No difference in pain scores between intercostal blocks and PM infiltration	No difference in pain scores between PM infiltration and placebo injection in second cohort of 15 patients

*Number of patients (active/control).

†Primary outcome(s) identified by bold font.

‡Primary outcome not defined.

ALND indicates axillary lymph node dissection; epi, epinephrine; GA, general anesthesia; intraop, intraoperative; IM, intramuscular; IV, intravenous; LA, local anesthetic; PACU, postanesthesia care unit; PO, per os; POD, postoperative day; PONV, postoperative nausea and vomiting; postop, postoperative; preop, preoperative; T, thoracic vertebral level; VAS, visual analog scale.

TABLE 2. Randomized Controlled Trials on Epidural Technique for Breast Surgery

Reference	Year	n*	Jadad Score	Type of Surgery	Details of Intervention	Control	Relevant Outcomes†	Acute Analgesia Results	Other Results
<i>Opioid only</i>									
Aida et al ⁶⁸	1999	14/15	4	Radical mastectomy	T3–T4, preop, morphine only (no LA) 0.06 mg/kg preop bolus and 0.02 mg/kg/h intraop infusion	Epidural saline	Pain VAS and postop morphine consumption (via PCEA) at 6, 12, 24, 48 h‡	Lower pain scores, less morphine consumption at all time points in preemptive epidural morphine group	
<i>Local anesthetic—intraoperative only</i>									
Yeh et al ⁶⁹	1999	32/32	2	Modified radical mastectomy	T5–6 or T6–7, preop, surgical block with lidocaine 2% to maintain C5–T6 level (no GA)	GA	Pain VAS at time of first analgesic, pethidine consumption at POD 2‡	Lower worst pain scores, less analgesic consumption, longer time to first analgesic in epidural group	Higher satisfaction, less adverse effects (PONV, dizziness, headache), lower cost in epidural group
Sundarathiti et al ⁷⁰	2005	25/25	3	Modified radical mastectomy with ALND	T4–5, preop, surgical block with ropivacaine 0.2% 10- to 15-mL bolus, intraop infusion of ropivacaine 0.2% 5–10 mL/h, epidural morphine 1.5 mg bolus and epidural discontinued at end of surgery; interscalene brachial plexus block, preop, ropivacaine 0.2% 8-mL bolus; intraoperative sedation (no GA)	GA with postop scheduled IV opioids	Pain NRS in PACU, 12, 24 h postop; postop rescue analgesic consumption in PACU and ward‡	Lower pain scores in PACU and 12 h postop, less rescue analgesic consumption in epidural group	No difference in PONV; higher patient satisfaction scores in epidural group
<i>Local anesthetic—continuous postoperative infusion</i>									
Correll et al ⁷¹	2001	9/9	3	Unilateral mastectomy with TRAM flap reconstruction	T8–T10, preop, 2 mg morphine bolus preop, intraop and postop infusion of ropivacaine 0.15% and morphine 0.05 mg/mL at 8 mL/h, discontinued POD 2	No epidural	Pain VAS at 6 time points from POD 1–4; length of stay	Lower pain scores at 3 of 6 time points (on POD 1–2), shorter hospital stay in epidural group	No difference in ambulation time, oral intake time, PONV, pruritus, constipation
Doss et al ⁷²	2001	30/30	5	Modified radical mastectomy	T6–7, preop, surgical block with ropivacaine 0.2% 5- to 10-mL bolus (plus 3- to 5-mL boluses as needed intraop, no GA), postop infusion of ropivacaine 0.2% 3–6 mL/h, discontinued 48 h postop	GA with postop scheduled IV opioids	Pain VRS at POD 0–3; time to PACU discharge readiness‡	Lower pain scores at POD 0–2, faster PACU discharge readiness in epidural group	Higher incidence of PONV in control group; higher patient satisfaction scores in epidural group

*Number of patients (active/control).

†Primary outcome(s) identified by bold font.

‡Primary outcome not defined.

ALND indicates axillary lymph node dissection; epi, epinephrine; GA, general anesthesia; intraop, intraoperative; IV, intravenous; LA, local anesthetic; LND, lymph node dissection; NRS, numeric rating scale; PACU, postanesthesia care unit; PCEA, patient-controlled epidural analgesia; POD, postoperative day; PONV, postoperative nausea and vomiting; postop, postoperative; preop, preoperative; T, thoracic vertebral level; TRAM, transverse rectus abdominis myocutaneous; VAS, visual analog scale.

TABLE 3. Randomized Controlled Trials on Paravertebral Block for Breast Surgery

Reference	Year	n *	Jadad Score	Type of Surgery	Details of Intervention	Control	Relevant Outcomes†	Acute Analgesia Results	Other Results
<i>Single-level injection</i>									
Pusch et al ⁷³	1999	44/42	2	Lumpectomy, mastectomy, with or without ALND	T4 injection, preop, Loss of Resistance technique, bupivacaine 0.5% 0.3 mL/kg; intraop sedation (no GA)	GA	Pain VAS hourly from 2–12 h; postop opioid and non-opioid analgesic consumption‡	Lower pain scores at all time points, less analgesic consumption in block group	Lower incidence of vomiting in block group
Terheggen et al ⁷⁴	2002	15/15	3	Lumpectomy, quadrantectomy with or without SLND, wire guided biopsy	T4 catheter, preop, LOR technique, surgical block with bupivacaine 0.5% 15–20 mL plus epi 2% 15–20 mL for patients undergoing preop radiographic wire localization); intraop sedation (no GA); discontinued at end of surgery	GA with propofol	Pain VAS at 15, 30, 60, 90, 120 min and discharge	Lower pain scores at 15–90 min and discharge in block group	No difference in recovery time, low incidence of PONV in both groups
Kairaluoma et al ^{75,76}	2004, 2006	30/30	4	Mastectomy or tumorectomy with SLND	T3 injection, preop, LOR technique, bupivacaine 0.5% 0.3 mL/kg bolus	Sham block with subcutaneous saline injection	Pain VAS and NRS at rest and movement every 30 min for 2 h; PACU oxycodone consumption	Lower pain scores at all time points, less PACU opioid consumption in LA group	Less PONV and sedation in PACU. Lower pain intensity with movement at 1 mo, lower incidence of pain symptoms at 6 mo, lower incidence and intensity of pain at rest and movement at 12 mo in LA group
Hura et al ⁷⁷	2006	35/35	3	Modified radical mastectomy with ALND	T4 injection, preop, LOR technique, surgical block with ropivacaine 0.5% 0.4 mL/kg; intraop sedation (no GA)	Same block technique, surgical block with bupivacaine 0.5% 0.4 mL/kg; intraop sedation (no GA)	Pain NRS at 0, 0.5, 1, 2, 24 h; postop analgesic consumption at 24 h; sensory block onset	No difference in pain scores or analgesic consumption. Faster sensory block onset in ropivacaine group	Increased sensory block at 24 h in ropivacaine group

Continued next page

TABLE 3. (Continued)

Reference	Year	n*	Jadad Score	Type of Surgery	Details of Intervention	Control	Relevant Outcomes†	Acute Analgesia Results	Other Results
Sidiropoulou et al ⁷⁸	2008	24/24	3	Modified radical mastectomy with ALND	T3 injection, preop, LOR technique, ropivacaine 0.5% 20 mL	Prior to closure, 2 wound catheters placed (one overlying PM, one in axilla), infusion with ropivacaine 0.5% 2 mL/h per catheter	Pain VAS every 4 h until 24 h; morphine consumption at 24 h	Lower pain scores at 4 h, but higher pain scores at 16 and 24 h in paravertebral group; no difference in opioid consumption	Less PONV in paravertebral group
Arunakul and Ruksa ⁷⁹	2010	10/10	2	Modified radical mastectomy	T4 injection, preop, LOR technique, bupivacaine 0.5% 0.3 mL/kg	No block	Pain NRS at rest and movement at 1 and 24 h; intraop opioid consumption; postop morphine consumption at 24 h	Lower pain scores at 1 h, less intraop and postop opioid consumption in block group	No difference in PONV
Gardiner et al ⁸⁰	2012	20/20	3	Augmentation (subpectoral)	T4 injection, bilateral, preop, LOR technique, ropivacaine 3 mg/kg plus epi in 40 mL total bolus; preop surgical field infiltration with saline; intraop sedation	Preop surgical field infiltration with ropivacaine; intraop sedation	Pain VAS and oral dextropropoxyphene requirement every 4 h POD 0–3‡	Lower postdischarge pain scores, less recovery room opioid consumption in paravertebral group	Improved intraop cooperation and reduced intraop sedation requirement in paravertebral group
Bhuvanewari et al ⁸¹	2012	36/12	5	Total mastectomy with ALND	T3 injection, preop, LOR technique, bolus with 0.3 mL/kg of either bupivacaine 0.25% plus epi (12 patients), bupivacaine 0.5% plus epi (12 patients), or bupivacaine 0.25% plus fentanyl 2 µg/mL	Saline paravertebral injection	Cumulative 24 h pain NRS at rest and movement; postop rescue analgesic consumption at 24 h ; time to first rescue analgesic	Lower cumulative pain scores at rest and movement, less rescue analgesic consumption, longer time to first rescue analgesic in patients receiving bupivacaine 0.5% or bupivacaine 0.25% plus fentanyl. No difference in patients receiving bupivacaine 0.25% alone	
Hassan and Mahran ⁸²	2015	45/45	5	Modified radical mastectomy	Preop, ultrasound guided, bupivacaine 0.25% 0.3 mL/kg plus magnesium sulphate 100 mg	Same block technique, bupivacaine 0.25% 0.3 mL/kg alone	Pain VAS at rest and movement at 0.5, 2, 4, 6, 12, 24 h; time to first analgesic request, morphine consumption at 24 h	Lower pain scores at all time points, longer time to first analgesic request, less morphine consumption in magnesium group	

<p><i>Multilevel injection</i> Klein et al⁸³ 2000</p>	30/30	3	Unilateral or bilateral mastectomy, augmentation, reconstruction	T1–T7 injections, preop, unilateral or bilateral, blind, surgical block with bupivacaine 0.5% plus epi 4-mL bolus per level; intraop sedation (no GA)	GA	Pain VAS and NRS at 0.5, 1, 24, 48, 72 h†	Lower pain scores at 0.5, 1, and 24 h in block group	Less severe nausea at 24 h
	30/30	3	Partial mastectomy, simple mastectomy, modified radical mastectomy	T1–T5 injections (3–5 injections depending on surgery type), preop, nerve stimulator guided, 3–3.5-mL bolus per level of a lidocaine 1.2% and bupivacaine 0.125% mixture containing epi, fentanyl 2.5 µg/mL and clonidine 15 µg/mL; intraop sedation (no GA)	GA	Pain VAS at rest and movement at 6, 12, 24, 36 h, POD 2–5; supplemental opioid requirement at 6, 12, 24, 36, 48, 72, 96, 120 h	Lower pain scores with movement at all time points, lower pain scores at rest at all time points from POD 0–3, less supplemental opioid requirement at all time points until 72 h in block group	Less PONV and shorter hospital stay in block group
<p>Moller et al⁸⁵ 2007</p>	38/41	5	Tumorectomy or mastectomy with SLND	C7–T5 injections, preop, blind, ropivacaine 0.5% 5-mL bolus per level (30 mL total)	Saline paravertebral injection	Pain NRS at 0, 0.5, 1, 1.5, 2 h, PACU discharge, POD 0–2; fentanyl consumption	Lower pain scores in the PACU only, less intraop and PACU opioid consumption in LA group. No differences after PACU discharge	No difference in PONV
<p>Boughey et al⁸⁶ 2009</p>	39/41	2	Partial mastectomy with SLND/ALND, mastectomy with or without SLND/ALND	T1–T6 injections, preop, LOR technique, ropivacaine 0.5%–1% plus epi, 3–6 mL per level	No block	Pain NRS and pain-free proportion at 0, 1, 3, 6 and 24 h ; postop analgesic consumption	Lower pain scores and pain-free proportion at 1 and 3 h in block group, higher pain scores at POD 1 in block group; no difference in postop analgesic consumption	No difference in PONV or time to discharge
<p>Omar et al⁸⁷ 2011</p>	21/19/20	5	Modified radical mastectomy	T1 and T4 injection, LOR technique, bupivacaine 0.5% 2 mg/kg plus ketamine 0.5 mg/kg (21 patients) or tramadol 1.5 mg/kg (19 patients)	Same block technique, bupivacaine 0.5% 2 mg/kg alone	Fentanyl consumption in PACU and at 24 h , pain VAS at 0, 1 h, PACU discharge, and 4, 8, 12, 18, 24 h	No differences in opioid consumption or pain scores	
<p>Das et al⁸⁸ 2012</p>	29/30	3	Lumpectomy	T3–6 injections, preop, LOR technique, surgical block with bupivacaine 0.5% 5-mL bolus per level; intraop sedation (no GA)	GA	Pain VAS at 0, 2, 4, 6, 12, 24 h; rescue analgesic consumption at 24 h; time to first rescue analgesic	Lower pain scores at 0, 2, 4 h, lower rescue analgesic consumption, longer time to first rescue analgesic in block group	Higher patient satisfaction scores in block group

Continued next page

TABLE 3. (Continued)

Reference	Year	n*	Jadad Score	Type of Surgery	Details of Intervention	Control	Relevant Outcomes†	Acute Analgesia Results	Other Results
Neja et al ⁸⁹	2013	28/26	5	Partial mastectomy, simple mastectomy, modified radical mastectomy with ALND	T1–T5 injections (3–5 surgery type), preop, nerve stimulator guided, surgical block with 0.06 mL/kg bolus per level of a lidocaine 1.25% and bupivacaine 0.175% mixture containing epi and clonidine 3.75 µg/mL; intraop sedation (no GA)	Same block technique and LA bolus without the addition of clonidine; intraop sedation (no GA)	Pain VAS and postop analgesic consumption at 6, 12, 24, 48, 72 h, 1 and 2 wk	Lower pain scores at rest and movement at 24, 48 and 72 h, less postop analgesic consumption at 48 h in clonidine group	Shorter time to resume daily activity in clonidine group
Abdallah et al ⁹⁰	2014	33/31	5	Partial mastectomy, mastectomy with and without SLND or ALND, mastectomy with implant insertion	T1–T5 injections, preop, ultrasound-guided, parasagittal approach, ropivacaine 0.5% 5 mL per level, GA with propofol-based Total Intravenous Anesthesia	Sham subcutaneous injection, GA with sevoflurane	Ambulatory quality of recovery score; pain VAS on POD 0, 2, 4, 7; intraop and postop morphine consumption	Higher quality of recovery scores at discharge and POD 2, lower pain scores on POD 0 and 2, less intraop and PACU opioid consumption in block group	Lower incidence of PONV, shorter time to discharge in block group
Mohamed et al ⁹¹	2014	30/30	5	Modified radical mastectomy with ALND	T1–T6 injections, preop, blind, bupivacaine 0.25% plus 1 µg/kg dexmedetomidine 3–4 mL per level	Same block technique, bolus with bupivacaine 0.25% alone	Pain VAS at 2, 4, 6, 12, 24, 36, 48 h; rescue analgesic consumption 48 h; time to first analgesic request‡	No difference in pain scores, but less rescue analgesic consumption and longer time to first analgesic request in dexmedetomidine group	
Fallalah and Mousa ⁹²	2016	20/20	3	Lumpectomy with ALND	T2–T6 injections, preop, blind, bupivacaine 0.5% 4 mL per level	Postop morphine PCA	Pain NRS at 1, 6, 12, 24 h, time to first analgesic request, morphine consumption at 24 h	Lower pain scores at 6 and 12 h, longer time to first analgesic request, less morphine consumption in paravertebral group	Lower incidence of PONV in paravertebral group
Wolf et al ⁹³	2016	35/39	2	Reconstructive prosthetic breast surgery	T1–T6 injections, preop, LOR technique, ropivacaine 0.5%–1% 3–6 mL per level	No block	Pain NRS at 0, 0–1, 1–3, 3–6, 18–22, 1 wk; intraop fentanyl consumption‡	Lower pain scores at 0–1, 1–3, 3–6 h, less intraop opioid consumption in block group	
<i>Continuous infusion</i>									
Buggy and Kerit ⁹⁴	2004	10/10	3	Mastectomy with LDMF	T3 or T4 catheter, preop, LOR technique, levobupivacaine 0.25% 10- to 15-mL bolus, infusion with levobupivacaine 0.25% 8–10 mL/h; discontinued at ≥24 h	No block, IV morphine	Pain VAS at rest and movement hourly until 20 h	Lower pain scores at rest and movement in block group	Higher flap tissue oxygen tension in block group

Burlacu et al ⁶⁵	2006	38/14	2	Mastectomy with ALND with or without flap reconstruction, partial mastectomy with ALND	T3 catheter, preop, LOR technique, levobupivacaine 0.25% 20-mL bolus plus either saline (13 patients), fentanyl 50 µg (13 patients), or clonidine 150 µg (12 patients); postop infusion with levobupivacaine 0.1% (13 patients), levobupivacaine 0.05% plus fentanyl 4 µg/mL (13 patients), or levobupivacaine 0.05% plus clonidine 3 µg/mL (12 patients) at 5–15 mL/h; discontinued at 48–72 h	No block	Pain VAS at 2, 4, 8, 12, 24 h; postop morphine consumption at 24 h via IV PCA	Lower pain scores at 4 h in block group; lower pain scores at 24 h and less opioid consumption at 24 h in block patients receiving LA additives (fentanyl or clonidine)	Increased nausea and vomiting in fentanyl patients; increased hypotension in clonidine patients
Iohom et al ⁶⁶	2006	14/15	2	Mastectomy or tumorectomy with ALND	T3 catheter, preop, LOR technique, bupivacaine 0.25% 10-mL bolus; infusion with bupivacaine 0.25%; discontinued ≤48 h	Standard analgesia with as needed opioid and non-opioid analgesics	Pain VAS at rest and movement at 0.5, 2, 4, 8, 12 h, and POD 2–5	Lower pain scores with movement at 0.5, 12 h, POD 1–5, lower pain scores at rest only at 0.5 h in block group	Lower incidence of pain at 2–3 mo in block group
McElwain et al ⁶⁶	2008	19/18	4	Mastectomy or wide local excision with and without ALND, with and without reconstruction	T2 or T3 catheter, preop, blind, levobupivacaine 0.25% 20-mL bolus pre-incision, 10 mL at wound closure; postop infusion with levobupivacaine 0.2% 8 mL/h, PCRA demand dose 3 mL every 15 min	Same catheter placement and levobupivacaine boluses and infusion; PCRA demand dose 8 mL every 30 min	Pain VAS at rest and movement every 4 h for 36 h ; postop rescue analgesic requirements	No difference in pain scores or rescue analgesic requirement between groups	
Buckenmaier et al ⁶⁷	2010	52/21	5	Lumpectomy with SLND/ALND, mastectomy, modified radical mastectomy	T3 catheter, preop, blind, surgical block with ropivacaine 0.5% 0.3 mL/kg with epi bolus, plus T1 and T6 injections with ropivacaine 1% with epi 5 mL each; intraop sedation (no GA); postop infusion with ropivacaine 0.1% (26 patients) or 0.2% (26 patients) at 10 mL/h; discontinued at 72 h	Same LA single injections and catheter placement; postop saline infusion	Pain scale at POD 1, 3, 5, 7 ; total inpatient and outpatient analgesic consumption	No difference in pain scores between groups (pain scores low in all groups); no difference in total analgesic consumption	Conversion to GA in 9 of 73 patients; no difference in nausea

Continued next page

TABLE 3. (Continued)

Reference	Year	n*	Jadad Score	Type of Surgery	Details of Intervention	Control	Relevant Outcomes†	Acute Analgesia Results	Other Results
Deegan et al ⁹⁸	2010	15/17	3	Partial mastectomy, mastectomy with ALND	T2 or T3 catheter, preop, LOR technique, levobupivacaine 0.25% 20-mL bolus; GA with propofol; postop infusion with levobupivacaine 0.25% 8–10 mL/h; discontinued at 48 h	No block, GA with sevoflurane and IV morphine	Pain VAS at 1, 2, 24 h; morphine consumption at 24 h	Lower pain scores at 1 and 2 h in block group. No difference at 24 h. Less morphine consumption in block group	No difference in the levels of the majority of serum cytokines studied
Abdelhalim ⁹⁹	2011	20/20	2	Partial mastectomy, modified radical mastectomy	T4 catheter, preop, LOR technique, lidocaine 2% 20-mL bolus, infusion with lidocaine 1% 5 mL/h with 5-mL boluses as needed	No block	Pain VAS at rest and movement at 30 min, 1, 2, 4, 12, 24 h, intraop fentanyl consumption and postop morphine consumption at 24 h‡	Lower pain scores, less intraop and postop opioid consumption in the block group, longer time to first analgesic request in block group	No difference in PONV
Ilfeld et al ¹⁰⁰	2014	30/30	5	Unilateral or bilateral mastectomy with or without ALND	T4 catheter, preop, unilateral or bilateral, ultrasound guided, parasagittal approach, ropivacaine 0.5% plus epi 1.5-mL bolus; infusion with ropivacaine 0.4% 5 mL/h; discontinued POD 3	Same catheter placement and ropivacaine bolus, saline infusion at 5 mL/h; discontinued POD 3	Brief Pain Inventory on POD 1, 4, 8, 28; opioid consumption on POD 0, 1, 4, 8	Lower pain inventory scores on POD 1, less opioid consumption only in the recovery room in LA infusion group	Lower pain inventory scores and less pain-induced dysfunction at 12 mo in LA infusion group
Karmakar et al ¹⁰¹	2014	117/60	3	Modified radical mastectomy with ALND	T3 catheter, preop, LOR technique, ropivacaine 2 mg/kg plus epi in 20-mL bolus; infusion with saline (57 patients) or ropivacaine 0.25% 0.1 mL/kg/h (60 patients); discontinued at 72 h	No block	Pain NRS at rest and movement at 0, 2, 4, 6, 12, 18, 24, 36, 48, 72 h; analgesic consumption in PACU and ward	No difference in acute pain scores or postop analgesic consumption	No difference in incidence of chronic pain at 3 and 6 mo. Less severe chronic pain in block group

Wu et al ¹⁰²	2015	187/ 199	3	Partial mastectomy with LND, simple mastectomy, modified radical mastectomy	T2–T4 catheter, bupivacaine 0.5% or ropivacaine 0.5% plus epi in 10- to 20-mL bolus; infusion with bupivacaine or ropivacaine 0.5% 6–10 mL/h; discontinued at ≤48 h; or T1–T5 single injections with ropivacaine 0.75% 5 mL per level; supplemental infiltration by surgeon to block cervical and contralateral thoracic nerves; deep sedation/GA with propofol	GA with sevoflurane	Pain VAS at 2 h; intraop opioid and postop long-acting opioid consumption at 2 h	Lower pain scores, less intraop and postop opioid consumption in the block group
-------------------------	------	-------------	---	---	---	---------------------	--	--

*Number of patients (active/control).
 †Primary outcome(s) identified by bold font.
 ‡Primary outcome not defined.
 ALND indicates axillary lymph node dissection; DIEP, deep inferior epigastric artery perforator; epi, epinephrine; GA, general anesthesia; intraop, intraoperative; IV, intravenous; LA, local anesthetic; LDMP, latissimus dorsi myocutaneous flap; LND, lymph node dissection; NRS, numeric rating scale; LOR, loss of resistance; PACU, postanesthesia care unit; PCA, patient-controlled analgesia; PCRA, patient-controlled regional anesthesia; PM, pectoralis major; POD, postoperative day; PONV, postoperative nausea and vomiting; postop, postoperative; preop, preoperative; T, thoracic vertebral level; TIVA, total intravenous anesthesia; SLND, sentinel lymph node dissection; VAS, visual analog scale.

Paravertebral Block

Thirty-one studies of PVB with a median Jadad score of 3 (range, 2–5) were included in the review. Of these, 10 studies^{73–81} used a single injection at 1 level, 11 studies^{83–86,88–91} utilized a single injection at multiple levels, and 10 studies^{9,94–102} utilized continuous infusions (Table 3). Single-level injections were performed at T2–T4, and multilevel injections were performed at 3 to 7 levels ranging from C7–T7. Twenty-three studies compared PVB to alternative analgesic approaches (ie, general anesthesia, intravenous opioids, local infiltration). All but 1 of these 24 studies¹⁰¹ identified analgesic benefit of PVB as indicated by pain scores, analgesic consumption, or time to first analgesic. It should be noted that only 4 of the 23 positive studies used a double-blind design.

The optimal dosing strategy with PVB for breast surgery (single injection, single injection with additives, or continuous infusion) remains unclear. The reported duration of analgesic benefit for patients with single-injection PVB varied between studies, with evidence of analgesia as late as postoperative day 3.⁸⁰

Additional outcomes were reported in several studies. Seven studies reported an improvement in postoperative nausea and vomiting,^{73,75,78,83,84,90,92} and 2 reported shortened length of hospital stay.^{84,90} In addition, 4 studies (only 2 of which were double-blind) demonstrated an improvement in pain incidence or characteristics at 1 to 12 postoperative months.^{9,76,101,103}

In summary, the literature supports PVB as an effective perioperative analgesic technique for breast surgery. Paravertebral block can also provide surgical anesthesia and may decrease nausea and vomiting, hospital stay, and chronic postsurgical pain. The use of paravertebral catheters has not reliably been demonstrated to be superior to a single-injection technique at 1 or multiple levels. Similar to epidurals, the safety of PVBs for outpatient surgery is a concern, given the trend toward outpatient performance of breast surgeries. Outpatient breast surgery with ambulatory paravertebral catheters has been described, but its analgesic benefit has not been demonstrated.^{97,100} Finally, further studies comparing PVB to local anesthetic infiltration are needed.

Brachial Plexus and Novel Peripheral Nerve Blocks

Brachial Plexus Blocks

One brachial plexus block study¹⁰⁴ with a Jadad score of 3 was included in the review (Table 4). Kaya et al¹⁰⁴ demonstrated analgesic benefit of relatively large-volume (30 mL) interscalene block alone for modified radical mastectomy. In addition, Sundarathiti et al⁷⁰ included an interscalene block as a supplement to TEA, but the study design prevents an assessment of the specific impact of the interscalene block (Table 2). In summary, although 1 study lends some support to the theoretical benefit of brachial plexus blocks, the undesirable upper-extremity block that results has prevented the incorporation of these approaches into clinical practice.

Interfascial Plane Blocks

No RCTs of Pecs I block were identified in our review. Four Pecs II block studies with a median Jadad score of 3 were included in our review^{105–108} (Table 4). Bashandy and Abbas¹⁰⁶ investigated Pecs II block versus no block for modified radical mastectomy in an observer-blinded study. They demonstrated reduced pain scores in the first 24 hours, reduced opioid consumption in the first 12 hours, less nausea and vomiting, less sedation, and shorter postanesthesia care unit and hospital stay in patients receiving Pecs II block. In an unblinded study, Wahba and Kamal¹⁰⁵ compared Pecs II block to single-injection, 1-level T4 paravertebral for modified radical mastectomy under

TABLE 4. Randomized Controlled Trials on Brachial Plexus and Novel Peripheral Nerve Blocks for Breast Surgery

Reference	Year	n*	Jadad Score	Type of Surgery	Details of Intervention	Control	Relevant Outcomes†	Acute Analgesia Results	Other Results
<i>Brachial plexus block</i>									
Kaya et al ¹⁰⁴	2013	30/30	3	Modified radical mastectomy with ALND	Interscalene brachial plexus block, postop, prior to emergence, nerve stimulator guided, bupivacaine 0.25% 30 mL	No block	Pain VAS at 0, 1, 2, 4, 6, 12, and 24 h; postop morphine consumption at 24 h	Lower pain scores at all time points from 0–12 h, less opioid consumption at 24 h in block group	Less PONV in block group
<i>Pecs II block</i>									
Wahba and Kamal ¹⁰⁵	2014	30/30	3	Modified radical mastectomy	Pecs II, preop, ultrasound guided, levobupivacaine 0.25% 10 mL between PM and Pm muscles and 20 mL superficial to SAM at level of ribs 2–4	T4 single-injection PVB, preop, LOR technique, levobupivacaine 0.25% 15–20 mL	Pain NRS at rest and movement at 1, 6, 12, 18, 24 h; postop morphine consumption at 24 h ; time to first analgesic request	Less opioid consumption at 24 h, longer time to first analgesic request, lower pain scores with movement at 1 h, lower pain scores at rest at 1, 6, 12 h in Pecs group. Higher pain scores at rest and movement at 18 and 24 h in Pecs group.	No difference in PONV
Bashandy and Abbas ¹⁰⁶	2015	60/60	3	Modified radical mastectomy	Pecs II, preop, ultrasound guided, bupivacaine 0.25% 10 mL between PM and Pm muscles and 20 mL superficial to SAM at level of 3rd rib	No block	Pain VAS at 0, 3, 6, 9, 24 h ; intraop fentanyl requirement postop morphine consumption at 0–4, 4–12, 12–24 h	Lower pain scores at all time points, less intraop opioid requirement, less opioid consumption at 0–12 h in block group	Lower PONV and sedation scores, shorter PACU and hospital stay in block group
Eldeen ¹⁰⁷	2016	20/20	2	Lumpectomy without ALND	Pecs II, preop, ultrasound guided, surgical block with bupivacaine 0.5% 10 mL plus 5 µg dexmedetomidine between PM and Pm muscles and 20 mL plus 10 µg dexmedetomidine superficial to SAM at level of ribs 2–4	T5–6 spinal, preop, hyperbaric bupivacaine 0.5% 1 mL plus dexmedetomidine 5 µg	Ability of blocks to provide surgical anesthesia ; pain VAS intraop and at 1, 2, 4, 8, 16, 24 h postop	All blocks provided adequate surgical anesthesia; lower pain scores at all time points in Pecs II group	Longer duration sensory (mean 16.6 h) and motor (mean 15.7 h) block in Pecs II group
Othman et al ¹⁰⁸	2016	30/30	4	Modified radical mastectomy	Pecs II, postinduction, ultrasound guided, bupivacaine 0.25% 30 mL plus ketamine 1 mg/kg in divided doses between PM and Pm muscles (10 mL) and superficial to SAM (20 mL) at level of ribs 2–4	Same block technique and LA bolus without the addition of ketamine	Pain VAS at 0, 2, 4, 6, 12, 24, 48 h, time to first rescue analgesic request, morphine consumption at 48 h	No difference in pain scores; longer time to first rescue analgesic and less opioid consumption in ketamine group	

*Number of patients (active/control).

†Primary outcome(s) identified by bold font.

ALND indicates axillary lymph node dissection; intraop, intraoperative; NRS, numeric rating scale; PACU, postanesthesia care unit; postop, postoperative; preop, preoperative; VAS, visual analog scale.

TABLE 5. Summary of the Evidence for Analgesic Procedures for Breast Surgery

Analgic Intervention	Technique	Anatomic Considerations	Indications	Need for Further Study
Intercostal nerve block (Table 1)	<ul style="list-style-type: none"> Multiple injections (3–6 levels), proximal to lateral cutaneous branch origin (angle of rib) 	<ul style="list-style-type: none"> No block of brachial plexus components 	<ul style="list-style-type: none"> Small body of evidence of analgesic benefit for lumpectomy and modified radical mastectomy Evidence of failure for submuscular augmentation 	<ul style="list-style-type: none"> Comparison with local anesthetic infiltration and interfascial plane blocks
Epidural block (Table 2)	<ul style="list-style-type: none"> T3–4 to T6–7 level epidural analgesia or anesthesia LA alone, in combination with opioid, or opioid alone 	<ul style="list-style-type: none"> Block of brachial plexus components only if cephalad spread 	<ul style="list-style-type: none"> Consistent evidence of analgesic benefit for mastectomy Continued benefit until catheter discontinuation 	
Paravertebral block (Table 3)	<ul style="list-style-type: none"> Single-level injection or continuous infusion at T2–T4 Multilevel injection at 3–7 levels from C7–T7 Catheters can be continued after home discharge No evidence of superiority of one technique 	<ul style="list-style-type: none"> No block of brachial plexus components 	<ul style="list-style-type: none"> Consistent evidence of analgesic benefit for all common breast surgeries 	<ul style="list-style-type: none"> Comparison with local anesthetic infiltration and interfascial plane blocks
Interscalene brachial plexus block (Table 4)	<ul style="list-style-type: none"> Interscalene approach alone has been studied in 1 RCT¹⁰⁴ 	<ul style="list-style-type: none"> Block of LTN Partial block of LPN, MPN, and TDN Frequent block of the supraclavicular nerves (superficial cervical plexus) No block of intercostobrachial nerve 	<ul style="list-style-type: none"> One RCT¹⁰⁴ showing analgesic benefit for modified radical mastectomy Anticipate benefit only for procedures producing myofascial pain (eg, submuscular augmentation, modified radical mastectomy) 	
Pecs I block	<ul style="list-style-type: none"> LA deposited between the PM and minor muscles Single injection or continuous infusion Alone or in combination with alternative blocks (eg, PVB) 	<ul style="list-style-type: none"> Block of LPN and MPN 	<ul style="list-style-type: none"> No RCTs Anticipate benefit for procedures producing myofascial pain (eg, submuscular augmentation) 	<ul style="list-style-type: none"> RCTs assessing magnitude of analgesic effect for subpectoral procedures
Pecs II block (Table 4)	<ul style="list-style-type: none"> Combination of 2 LA depositions <ul style="list-style-type: none"> Between the PM and minor muscles (as with Pecs I) Between the Pm and SAMs at level of ribs 2–4 <ul style="list-style-type: none"> Modified injection deep to the SAM has also been described⁵⁷ 	<ul style="list-style-type: none"> Block of LPN, MPN, LTN, and TDN, anterior divisions of the lateral cutaneous branches of the intercostal nerves (T2–4, occasionally to T6) No block of ACBs of the intercostal nerves 	<ul style="list-style-type: none"> 2 RCTs showing analgesic benefit for modified radical mastectomy^{105,106} 	<ul style="list-style-type: none"> Comparison with paravertebral and with local anesthetic infiltration Benefit of catheter technique Assessment of risk, especially in comparison to paravertebral

Continued next page

TABLE 5. (Continued)

Analgesic Intervention	Technique	Anatomic Considerations	Indications	Need for Further Study
Serratus plane block	<ul style="list-style-type: none"> • LA deposited deep to the latissimus dorsi muscle, either superficial or deep to the SAM, at level of rib 5 in the midaxillary line • Alone or in combination with Pecs I block 	<ul style="list-style-type: none"> • Block of LTN, TDN, anterior divisions of the lateral cutaneous branches of the intercostal nerves (T2-9) • No block of LPN, MPN, or ACBs of the intercostal nerves 	<ul style="list-style-type: none"> • No RCTs 	<ul style="list-style-type: none"> • RCTs assessing analgesic benefit and comparing with other techniques • Further comparison with deep injection of Pecs II block regarding distribution and duration
Blocks of the ACBs of the intercostal nerves	<ul style="list-style-type: none"> • PIFB: LA deposited between the PM and external intercostal muscles • Transversus thoracic muscle plane block: LA deposited between the internal intercostal and transversus thoracic muscles 	<ul style="list-style-type: none"> • No block of lateral cutaneous branches of the intercostal nerves • No block of brachial plexus components 	<ul style="list-style-type: none"> • No RCTs 	<ul style="list-style-type: none"> • Evaluation of the reliability, analgesic impact, and necessity of these approaches

LA indicates local anesthetic.

general anesthesia. They demonstrated reduced analgesic consumption at 24 hours, longer time to first analgesic request, and some reduction in pain scores in the first 12 hours with Pecs II block. Despite the use of levobupivacaine in both blocks, pain scores were higher at 16 and 24 hours in the Pecs II block group, suggesting shorter duration of effect with Pecs II than PVB despite improved early analgesia. Eldeen¹⁰⁷ demonstrated that Pecs II blocks can provide effective surgical anesthesia for lumpectomy without axillary lymph node dissection and a sensory block extending to a mean of 16.6 hours when using bupivacaine 0.5% combined with low-dose dexmedetomidine.

No RCTs of SPB, PIFB, or TTP block were identified in our review.

The biggest impact of interfascial peripheral nerve blocks could be their relative ease to perform and potentially low risk profile. Because of the peripheral nature of these blocks, sympathetic blockade is not expected, risk of serious bleeding is likely low, and, as with other ultrasound-guided interfascial blocks, performance of the block in both awake and anesthetized patients may be safe. Although the novel interfascial blocks hold promise, there is a clear paucity of high-quality evidence supporting the analgesic efficacy and addressing the safety of these approaches. Randomized controlled trials comparing the various technical approaches to one another and comparing the interfascial blocks to alternative techniques (especially local anesthetic infiltration and PVB) are needed.

CONCLUSIONS

Acute pain following breast surgery is common, and numerous options exist for perioperative analgesia. An understanding of the anatomy of the breast and the anatomic structures disrupted by various surgical procedures will aid in selecting the appropriate perioperative analgesic technique and evaluating new techniques as they are described in the literature. We summarize the innervation, surgical procedures, and analgesic procedures in Figure 8 and the evidence for each of the analgesic procedures in Table 5. Both epidural and PVBs have been shown to provide effective analgesia for breast surgery. Paravertebral block has consistently been demonstrated to enhance analgesia while improving additional aspects of postoperative recovery, but further RCTs comparing PVB directly to local anesthetic infiltration are needed. Novel interfascial peripheral nerve blocks show promise as they may be easier to perform, may decrease risk, may be more suitable for outpatient procedures, and may even provide more complete analgesia by blocking both intercostal and brachial plexus–derived nerves. Although enticing, these assertions remain unproven. Randomized trials are needed to determine the safety and efficacy of the newer peripheral blocks, especially as compared with alternative analgesic techniques.

ACKNOWLEDGMENTS

The authors thank Anna Getselman, executive director, Health Sciences Library, Columbia University Medical Center, for her significant contributions to the literature review.

REFERENCES

1. Vilholm OJ, Cold S, Rasmussen L, Sindrup SH. The postmastectomy pain syndrome: an epidemiological study on the

- prevalence of chronic pain after surgery for breast cancer. *Br J Cancer*. 2008;99:604–610.
2. Cheville AL, Tchou J. Barriers to rehabilitation following surgery for primary breast cancer. *J Surg Oncol*. 2007;95:409–418.
 3. Roth RS, Lowery JC, Davis J, Wilkins EG. Persistent pain following postmastectomy breast reconstruction: long-term effects of type and timing of surgery. *Ann Plast Surg*. 2007;58:371–376.
 4. Belfer I, Schreiber KL, Shaffer JR, et al. Persistent postmastectomy pain in breast cancer survivors: analysis of clinical, demographic, and psychosocial factors. *J Pain*. 2013;14:1185–1195.
 5. Gärtner R, Jensen MB, Nielsen J, Ewertz M, Kroman N, Kehlet H. Prevalence of and factors associated with persistent pain following breast cancer surgery. *JAMA*. 2009;302:1985–1992.
 6. Cho AR, Kwon JY, Kim KH, et al. The effects of anesthetics on chronic pain after breast cancer surgery. *Anesth Analg*. 2013;116:685–693.
 7. Bokhari FN, McMillan DE, McClement S, Daeninck PJ. Pilot study of a survey to identify the prevalence of and risk factors for chronic neuropathic pain following breast cancer surgery. *Oncol Nurs Forum*. 2012;39:E141–E149.
 8. Fassoulaki A, Melemini A, Staikou C, Triga A, Sarantopoulos C. Acute postoperative pain predicts chronic pain and long-term analgesic requirements after breast surgery for cancer. *Acta Anaesthesiol Belg*. 2008;59:241–248.
 9. Iohom G, Abdalla H, O'Brien J, et al. The associations between severity of early postoperative pain, chronic postsurgical pain and plasma concentration of stable nitric oxide products after breast surgery. *Anesth Analg*. 2006;103:995–1000.
 10. Poleshuck EL, Katz J, Andrus CH, et al. Risk factors for chronic pain following breast cancer surgery: a prospective study. *J Pain*. 2006;7:626–634.
 11. Andersen KG, Duriand HM, Jensen HE, Kroman N, Kehlet H. Predictive factors for the development of persistent pain after breast cancer surgery. *Pain*. 2015;156:2413–2422.
 12. Wallace MS, Wallace AM, Lee J, Dobke MK. Pain after breast surgery: a survey of 282 women. *Pain*. 1996;66:195–205.
 13. Jadad AR, Moore RA, Carroll D, et al. Assessing the quality of reports of randomized clinical trials: is blinding necessary? *Control Clin Trials*. 1996;17:1–12.
 14. Siddiqi MA, Mullick AN. On the anatomy of intercostal spaces in man and certain other mammals. *J Anat*. 1935;69:350–355.
 15. Davies F, Gladstone RJ, Stibbe EP. The anatomy of the intercostal nerves. *J Anat*. 1932;66:323–333.
 16. Jaspars JJ, Posma AN, van Immerseel AA, Gittenberger-de Groot AC. The cutaneous innervation of the female breast and nipple-areola complex: implications for surgery. *Br J Plast Surg*. 1997;50:249–259.
 17. Sarhadi NS, Shaw Dunn J, Lee FD, Soutar DS. An anatomical study of the nerve supply of the breast, including the nipple and areola. *Br J Plast Surg*. 1996;49:156–164.
 18. Cooper A. *On the Anatomy of the Breast*. London: Longman, Orme, Green, Brown, and Longmans; 1840.
 19. Craig RD, Sykes PA. Nipple sensitivity following reduction mammoplasty. *Br J Plast Surg*. 1970;23:165–172.
 20. Michelle le Roux C, Kiil BJ, Pan WR, Rozen WM, Ashton MW. Preserving the neurovascular supply in the Hall-Findlay superomedial pedicle breast reduction: an anatomical study. *J Plast Reconstr Aesthet Surg*. 2010;63:655–662.
 21. Schlenz I, Kuzbari R, Gruber H, Holle J. The sensitivity of the nipple-areola complex: an anatomic study. *Plast Reconstr Surg*. 2000;105:905–909.
 22. Riccio CA, Zeiderman MR, Chowdhry S, et al. Plastic surgery of the breast: keeping the nipple sensitive. *Eplasty*. 2015;15:e28.
 23. Loukas M, Louis RG Jr, Fogg QA, Hallner B, Gupta AA. An unusual innervation of pectoralis minor and major muscles from a branch of the intercostobrachial nerve. *Clin Anat*. 2006;19:347–349.
 24. Loukas M, Hullett J, Louis RG Jr, Holdman S, Holdman D. The gross anatomy of the extrathoracic course of the intercostobrachial nerve. *Clin Anat*. 2006;19:106–111.
 25. O'Rourke MG, Tang TS, Allison SI, Wood W. The anatomy of the extrathoracic intercostobrachial nerve. *Aust N Z J Surg*. 1999;69:860–864.
 26. Kwekkeboom K. Postmastectomy pain syndromes. *Cancer Nurs*. 1996;19:37–43.
 27. Vecht CJ, van de Brand HJ, Wajer OJ. Post-axillary dissection pain in breast cancer due to a lesion of the intercostobrachial nerve. *Pain*. 1989;38:171–176.
 28. Corriveau S, Jacobs JS. Macromastia in adolescence. *Clin Plast Surg*. 1990;17:151–160.
 29. Macchi V, Tiengo C, Porzionato A, et al. Medial and lateral pectoral nerves: course and branches. *Clin Anat*. 2007;20:157–162.
 30. Porzionato A, Macchi V, Stecco C, et al. Surgical anatomy of the pectoral nerves and the pectoral musculature. *Clin Anat*. 2012;25:559–575.
 31. Arad E, Li Z, Sitzman TJ, Agur AM, Clarke HM. Anatomic sites of origin of the suprascapular and lateral pectoral nerves within the brachial plexus. *Plast Reconstr Surg*. 2014;133:20e–27e.
 32. Hoffman GW, Elliott LF. The anatomy of the pectoral nerves and its significance to the general and plastic surgeon. *Ann Surg*. 1987;205:504–507.
 33. Moosman DA. Anatomy of the pectoral nerves and their preservation in modified mastectomy. *Am J Surg*. 1980;139:883–886.
 34. Loukas M, Louis RG Jr, Fitzsimmons J, Colborn G. The surgical anatomy of the ansa pectoralis. *Clin Anat*. 2006;19:685–693.
 35. Tubbs RS, Jones VL, Loukas M, et al. Anatomy and landmarks for branches of the brachial plexus: a vade mecum. *Surg Radiol Anat*. 2010;32:261–270.
 36. Bremner-Smith AT, Unwin AJ, Williams WW. Sensory pathways in the spinal accessory nerve. *J Bone Joint Surg Br*. 1999;81:226–228.
 37. Layeeque R, Hochberg J, Siegel E, et al. Botulinum toxin infiltration for pain control after mastectomy and expander reconstruction. *Ann Surg*. 2004;240:608–613.
 38. Huang TT. Breast and subscapular pain following submuscular placement of breast prostheses. *Plast Reconstr Surg*. 1990;86:275–280.
 39. Mense S. Nociception from skeletal muscle in relation to clinical muscle pain. *Pain*. 1993;54:241–289.
 40. Wallace AM, Wallace MS. Postmastectomy and postthoracotomy pain. *Anesthesiol Clin North Am*. 1997;15:353–370.
 41. Anderson BO, Masetti R, Silverstein MJ. Oncoplastic approaches to partial mastectomy: an overview of volume-displacement techniques. *Lancet Oncol*. 2005;6:145–157.
 42. Warren Peled A, Foster RD, Stover AC, et al. Outcomes after total skin-sparing mastectomy and immediate reconstruction in 657 breasts. *Ann Surg Oncol*. 2012;19:3402–3409.
 43. Loukas M, Tubbs RS, Mirzayan N, Shirak M, Steinberg A, Shoja MM. The history of mastectomy. *Am Surg*. 2011;77:566–571.
 44. Vadivelu N, Schreck M, Lopez J, Kodumudi G, Narayan D. Pain after mastectomy and breast reconstruction. *Am Surg*. 2008;74:285–296.
 45. Cordeiro PG. Breast reconstruction after surgery for breast cancer. *N Engl J Med*. 2008;359:1590–1601.
 46. Cordeiro PG, McCarthy CM. A single surgeon's 12-year experience with tissue expander/implant breast reconstruction: part I. A prospective analysis of early complications. *Plast Reconstr Surg*. 2006;118:825–831.
 47. Bajaj AK, Chevray PM, Chang DW. Comparison of donor-site complications and functional outcomes in free muscle-sparing TRAM

- flap and free DIEP flap breast reconstruction. *Plast Reconstr Surg.* 2006; 117:737–746.
48. Kroll SS, Sharma S, Koutz C, et al. Postoperative morphine requirements of free TRAM and DIEP flaps. *Plast Reconstr Surg.* 2001;107:338–341.
 49. Ghaderi B, Hoenig JM, Dado D, Angelats J, Vandevender D. Incidence of intercostobrachial nerve injury after transaxillary breast augmentation. *Aesthet Surg J.* 2002;22:26–32.
 50. Hidalgo DA, Pusic AL. The role of methocarbamol and intercostal nerve blocks for pain management in breast augmentation. *Aesthet Surg J.* 2005; 25:571–575.
 51. von Sperling ML, Hoimyr H, Finnerup K, Jensen TS, Finnerup NB. Persistent pain and sensory changes following cosmetic breast augmentation. *Eur J Pain.* 2011;15:328–332.
 52. Kopacz DJT, GE. Intercostal blocks for thoracic and abdominal surgery. *Tech Reg Anesth Pain Manag.* 1998;2:25–29.
 53. Karmakar MK. Thoracic paravertebral block. *Anesthesiology.* 2001;95: 771–780.
 54. Bigeleisen P, Wilson M. A comparison of two techniques for ultrasound guided infraclavicular block. *Br J Anaesth.* 2006;96:502–507.
 55. Blanco R. The ‘Pecs block’: a novel technique for providing analgesia after breast surgery. *Anaesthesia.* 2011;66:847–848.
 56. Blanco R, Fajardo M, Maldonado TP. Ultrasound description of Pecs II (modified Pecs I): a novel approach to breast surgery. *Rev Esp Anestesiol Reanim.* 2012;1–6.
 57. Pérez MF, Duany O, de la Torre PA. Redefining Pecs blocks for postmastectomy analgesia. *Reg Anesth Pain Med.* 2015;40:729–730.
 58. Blanco R, Parras T, McDonnell JG, Prats-Galino A. Serratus plane block: a novel ultrasound-guided thoracic wall nerve block. *Anaesthesia.* 2013; 68:1107–1113.
 59. De la Torre PA, García PD, Alvarez SL, Miguel FJ, Pérez MF. A novel ultrasound-guided block: a promising alternative for breast analgesia. *Aesthet Surg J.* 2014;34:198–200.
 60. Alfaro-de la Torre P, Fajardo-Pérez M. Thoracic paravertebral block and its effects on chronic pain and health-related quality of life after modified radical mastectomy. *Reg Anesth Pain Med.* 2015;40:177–178.
 61. Ueshima H, Kitamura A. Blocking of multiple anterior branches of intercostal nerves (Th2–6) using a transversus thoracic muscle plane block. *Reg Anesth Pain Med.* 2015;40:388.
 62. Henriquez-Pino JA, Gomes WJ, Prates JC, Buffolo E. Surgical anatomy of the internal thoracic artery. *Ann Thorac Surg.* 1997;64:1041–1045.
 63. Sopena-Zubiria LA, Cuellar-Martinez A, Galan Gutierrez JC, Fernandez-Mere LA. Reply to the article entitled ultrasound description of Pecs II (modified Pecs I): a novel approach to breast surgery. *Rev Esp Anestesiol Reanim.* 2013;60:295.
 64. Atanassoff PG, Alon E, Pasch T, Ziegler WH, Gautschi K. Intercostal nerve block for minor breast surgery. *Reg Anesth.* 1991;16:23–27.
 65. Atanassoff PG, Alon E, Weiss BM. Intercostal nerve block for lumpectomy: superior postoperative pain relief with bupivacaine. *J Clin Anesth.* 1994;6:47–51.
 66. Fassoulaki A, Sarantopoulos C, Melemini A, Hogan Q. Regional block and mexiletine: the effect on pain after cancer breast surgery. *Reg Anesth Pain Med.* 2001;26:223–228.
 67. Nasr MW, Habre SB, Jabbour H, Baradhi A, El Asmar Z. A randomized controlled trial of postoperative pain control after subpectoral breast augmentation using intercostal nerve block versus bupivacaine pectoralis major infiltration: a pilot study. *J Plast Reconstr Aesthet Surg.* 2015;68: e83–e84.
 68. Aida S, Baba H, Yamakura T, Taga K, Fukuda S, Shimoji K. The effectiveness of preemptive analgesia varies according to the type of surgery: a randomized, double-blind study. *Anesth Analg.* 1999;89: 711–716.
 69. Yeh CC, Yu JC, Wu CT, Ho ST, Chang TM, Wong CS. Thoracic epidural anesthesia for pain relief and postoperation recovery with modified radical mastectomy. *World J Surg.* 1999;23:256–260.
 70. Sundarathiti P, Pasutharnchat K, Kongdan Y, Suranutkarin PE. Thoracic epidural anesthesia (TEA) with 0.2% ropivacaine in combination with ipsilateral brachial plexus block (BPB) for modified radical mastectomy (MRM). *J Med Assoc Thai.* 2005;88:513–520.
 71. Correll DJ, Viscusi ER, Grunwald Z, Moore JH Jr. Epidural analgesia compared with intravenous morphine patient-controlled analgesia: postoperative outcome measures after mastectomy with immediate TRAM flap breast reconstruction. *Reg Anesth Pain Med.* 2001;26: 444–449.
 72. Doss NW, Ipe J, Crimi T, et al. Continuous thoracic epidural anesthesia with 0.2% ropivacaine versus general anesthesia for perioperative management of modified radical mastectomy. *Anesth Analg.* 2001;92: 1552–1557.
 73. Pusch F, Freitag H, Weinstabl C, Obwegeser R, Huber E, Wildling E. Single-injection paravertebral block compared to general anaesthesia in breast surgery. *Acta Anaesthesiol Scand.* 1999;43:770–774.
 74. Terheggen MA, Wille F, Borel Rinkes IH, Ionescu TI, Knape JT. Paravertebral blockade for minor breast surgery. *Anesth Analg.* 2002;94: 355–359.
 75. Kairaluoma PM, Bachmann MS, Korpinen AK, Rosenberg PH, Pere PJ. Single-injection paravertebral block before general anesthesia enhances analgesia after breast cancer surgery with and without associated lymph node biopsy. *Anesth Analg.* 2004;99:1837–1843.
 76. Kairaluoma PM, Bachmann MS, Rosenberg PH, Pere PJ. Preincisional paravertebral block reduces the prevalence of chronic pain after breast surgery. *Anesth Analg.* 2006;103:703–708.
 77. Hura G, Knapik P, Misiulek H, Krakus A, Karpe J. Sensory blockade after thoracic paravertebral injection of ropivacaine or bupivacaine. *Eur J Anaesthesiol.* 2006;23:658–664.
 78. Sidiropoulou T, Buonomo O, Fabbi E, et al. A prospective comparison of continuous wound infiltration with ropivacaine versus single-injection paravertebral block after modified radical mastectomy. *Anesth Analg.* 2008;106:997–1001.
 79. Arunakul P, Ruksa A. General anesthesia with thoracic paravertebral block for modified radical mastectomy. *J Med Assoc Thai.* 2010;93(suppl 7): S149–S153.
 80. Gardiner S, Rudkin G, Cooter R, Field J, Bond M. Paravertebral blockade for day-case breast augmentation: a randomized clinical trial. *Anesth Analg.* 2012;115:1053–1059.
 81. Bhuvanewari V, Wig J, Mathew PJ, Singh G. Post-operative pain and analgesic requirements after paravertebral block for mastectomy: a randomized controlled trial of different concentrations of bupivacaine and fentanyl. *Indian J Anaesth.* 2012;56:34–39.
 82. Hassan ME, Mahran E. Effect of adding magnesium sulphate to bupivacaine on the clinical profile of ultrasound-guided thoracic paravertebral block in patients undergoing modified radical mastectomy. *Eg J Anaesth.* 2015;31:23–27.
 83. Klein SM, Bergh A, Steele SM, Georgiade GS, Greengrass RA. Thoracic paravertebral block for breast surgery. *Anesth Analg.* 2000;90: 1402–1405.
 84. Naja MZ, Ziade MF, Lönnqvist PA. Nerve-stimulator guided paravertebral blockade vs. general anaesthesia for breast surgery: a prospective randomized trial. *Eur J Anaesthesiol.* 2003;20: 897–903.
 85. Moller JF, Nikolajsen L, Rodt SA, Ronning H, Carlsson PS. Thoracic paravertebral block for breast cancer surgery: a randomized double-blind study. *Anesth Analg.* 2007;105:1848–1851.

86. Boughey JC, Goravanchi F, Parris RN, et al. Prospective randomized trial of paravertebral block for patients undergoing breast cancer surgery. *Am J Surg.* 2009;198:720–725.
87. Omar AM, Mansour MA, Abdelwahab HH, et al. Role of ketamine and tramadol as adjuncts to bupivacaine 0.5% in paravertebral block for breast surgery: a randomized double-blind study. *Eg J Anaesth.* 2011;27:101–105.
88. Das S, Bhattacharya P, Mandal MC, Mukhopadhyay S, Basu SR, Mandol BK. Multiple-injection thoracic paravertebral block as an alternative to general anaesthesia for elective breast surgeries: a randomised controlled trial. *Indian J Anaesth.* 2012;56:27–33.
89. Naja ZM, Ziade FM, El-Rajab MA, Naccash N, Ayoubi JM. Guided paravertebral blocks with versus without clonidine for women undergoing breast surgery: a prospective double-blinded randomized study. *Anesth Analg.* 2013;117:252–258.
90. Abdallah FW, Morgan PJ, Cil T, et al. Ultrasound-guided multilevel paravertebral blocks and total intravenous anesthesia improve the quality of recovery after ambulatory breast tumor resection. *Anesthesiology.* 2014;120:703–713.
91. Mohamed SA, Fares KM, Mohamed AA, Alieldin NH. Dexmedetomidine as an adjunctive analgesic with bupivacaine in paravertebral analgesia for breast cancer surgery. *Pain Physician.* 2014;17:E589–E598.
92. Fallatah S, Mousa W. Multiple levels paravertebral block versus morphine patient-controlled analgesia for postoperative analgesia following breast cancer surgery with unilateral lumpectomy, and axillary lymph nodes dissection. *Saudi J Anaesth.* 2016;10:13–17.
93. Wolf O, Clemens MW, Purugganan RV, et al. A prospective, randomized, controlled trial of paravertebral block versus general anesthesia alone for prosthetic breast reconstruction. *Plast Reconstr Surg.* 2016;137:660e–666e.
94. Buggy DJ, Kerin MJ. Paravertebral analgesia with levobupivacaine increases postoperative flap tissue oxygen tension after immediate latissimus dorsi breast reconstruction compared with intravenous opioid analgesia. *Anesthesiology.* 2004;100:375–380.
95. Burlacu CL, Frizelle HP, Moriarty DC, Buggy DJ. Fentanyl and clonidine as adjunctive analgesics with levobupivacaine in paravertebral analgesia for breast surgery. *Anaesthesia.* 2006;61:932–937.
96. McElwain J, Freir NM, Burlacu CL, Moriarty DC, Sessler DI, Buggy DJ. The feasibility of patient-controlled paravertebral analgesia for major breast cancer surgery: a prospective, randomized, double-blind comparison of two regimens. *Anesth Analg.* 2008;107:665–668.
97. Buckenmaier CC 3rd, Kwon KH, Howard RS, et al. Double-blinded, placebo-controlled, prospective randomized trial evaluating the efficacy of paravertebral block with and without continuous paravertebral block analgesia in outpatient breast cancer surgery. *Pain Med.* 2010;11:790–799.
98. Deegan CA, Murray D, Doran P, et al. Anesthetic technique and the cytokine and matrix metalloproteinase response to primary breast cancer surgery. *Reg Anesth Pain Med.* 2010;35:490–495.
99. Abdel-halim JMK. Continuous thoracic paravertebral block: an adjunct to general anaesthesia in major breast surgery. *Eg J Anaesth.* 2011;27:83–87.
100. Ilfeld BM, Madison SJ, Suresh PJ, et al. Treatment of postmastectomy pain with ambulatory continuous paravertebral nerve blocks: a randomized, triple-masked, placebo-controlled study. *Reg Anesth Pain Med.* 2014;39:89–96.
101. Karmakar MK, Samy W, Li JW, et al. Thoracic paravertebral block and its effects on chronic pain and health-related quality of life after modified radical mastectomy. *Reg Anesth Pain Med.* 2014;39:289–298.
102. Wu J, Buggy D, Fleischmann E, et al. Thoracic paravertebral regional anesthesia improves analgesia after breast cancer surgery: a randomized controlled multicentre clinical trial. *Can J Anaesth.* 2015;62:241–251.
103. Ilfeld BM, Madison SJ, Suresh PJ, et al. Persistent postmastectomy pain and pain-related physical and emotional functioning with and without a continuous paravertebral nerve block: a prospective 1-year follow-up assessment of a randomized, triple-masked, placebo-controlled study. *Ann Surg Oncol.* 2015;22:2017–2025.
104. Kaya M, Oguz G, Senel G, Kadiogullari N. Postoperative analgesia after modified radical mastectomy: the efficacy of interscalene brachial plexus block. *J Anesth.* 2013;27:862–867.
105. Wahba SS, Kamal SM. Thoracic paravertebral block versus pectoral nerve block for analgesia after breast surgery. *Eg J Anaesth.* 2014;30:129–135.
106. Bashandy GM, Abbas DN. Pectoral nerves i and ii blocks in multimodal analgesia for breast cancer surgery: a randomized clinical trial. *Reg Anesth Pain Med.* 2015;40:68–74.
107. Eldeen HMS. Ultrasound guided pectoral nerve blockade versus thoracic spinal blockade for conservative breast surgery in cancer breast: a randomized controlled trial. *Eg J Anaesth.* 2016;32:29–35.
108. Othman AH, El-Rahman AM, El Sherif F. Efficacy and safety of ketamine added to local anesthetic in modified pectoral block for management of postoperative pain in patients undergoing modified radical mastectomy. *Pain Physician.* 2016;19:485–494.