

Aneurysm-Rainbow Team/Helsinki

Principles of neuroanesthesia in aneurysmal subarachnoid hemorrhage: the Helsinki experience

Tarja Randell, MD, PhD^{a,*}, Mika Niemelä, MD, PhD^b, Juha Kyttä, MD, PhD^a, Päivi Tanskanen, MD^a, Markku Määttä, MD^a, Ayse Karatas, MD^b, Keisuke Ishii, MD, PhD^b, Reza Dashti, MD^b, Hu Shen, MD^b, Juha Hernesniemi, MD, PhD^b

Departments of ^aNeuroanesthesia, and ^bNeurosurgery, Helsinki University Central Hospital, Helsinki 00260, Finland

Received 8 March 2006; accepted 29 April 2006

Abstract

Background: Aneurysmal subarachnoid hemorrhage is a devastating disease that is followed by a marked stress response affecting other organs besides the brain. The aim in the management of patients with aSAH is not only to prevent rebleedings by treating the aneurysm by either microneurosurgery or endovascular surgery, but also to evacuate acute space-occupying hematomas and to treat hydrocephalus.

Methods: This review is based on the experience of the authors in the management of more than 7500 patients with aSAH treated in the Department of Neurosurgery at Helsinki University Central Hospital, Finland.

Results: The role of the neuroanesthesiologist together with the neurosurgeon may begin in the emergency department to assess and stabilize the general medical and neurologic status of the patients. Early preoperative management of patients in the NICU, prevention of rebleeding, and providing a slack brain during microneurosurgical procedures are further steps. Postoperative management, prevention, and treatment of possible medical complications and cerebrovascular spasm are as necessary as high-quality microsurgery.

Conclusion: Multidisciplinary and professional teamwork is essential in the management of patients with cerebral aneurysms.

© 2006 Elsevier Inc. All rights reserved.

Keywords:

Aneurysm; Cerebral; Subarachnoid hemorrhage; Microsurgery; Neuroanesthesia

1. Aneurysmal subarachnoid hemorrhage

Subarachnoid hemorrhage is a devastating disease followed by a marked stress response with elevated plasma

Abbreviations: ASA, American Society of Anesthesiologists; aSAH, aneurysmal subarachnoid hemorrhage; CSF, cerebrospinal fluid; CTA, computed tomography angiography; DHPB, dehydrobenzperidole; DSA, digitally subtracted angiography; ECG, electrocardiography; GCS, Glasgow Coma Scale; ICH, intracerebral hemorrhage; ICP, intracranial pressure; IHAST, Intraoperative Hypothermia for Aneurysm Surgery Trial; IVH, intraventricular hemorrhage; MAC, minimal alveolar concentration; NICU, neurosurgical intensive care unit; NSAID, nonsteroidal anti-inflammatory drug; OR, operation room; SOPs, standard operation practices; WFNS, World Federation of Neurological Surgeons.

* Corresponding author. Tel.: +358 50 4270612; fax: +358 9 47187560.

E-mail address: tarja.randell@hus.fi (T. Randell).

concentrations of catecholamines and electrolyte imbalance. Hypokalemia occurs frequently, whereas hyponatremia is a late finding in up to 56% of the patients [8,20,23]. Most often, the patients present with a high blood glucose level, which has been related to the poor outcome after SAH [5]. Dehydration can be a result of nausea and vomiting often present after ictus. Cardiopulmonary disturbances are common, presenting as cardiac arrhythmias, myocardial ischemia, cardiac failure, and neurogenic pulmonary edema. Electrocardiography changes such as increased QT interval and QT depression as well as arrhythmias may be detected in the early phase also in patients without any known heart disease. The ECG changes typically subside within a few days. The pathophysiology of the pulmonary edema remains to be elucidated, whereas the cardiac disorders are considered as consequences of the stress response. Also, in many cases, there is temporary

loss of consciousness at the time of SAH, predisposing to pulmonary aspiration of the gastric contents often resulting in severe pulmonary complications [9–11, 17,23]. Neurologic status on admission after SAH is described by using the Hunt and Hess or the WFNS (World Federation of Neurological Surgeons) classification. Fisher classification is used to describe the amount of blood on CT [6,9].

There are good reasons to consider aSAH a systemic disease rather than an incident affecting only one organ—the brain; therefore, the ASA class is always IV or V. Our long-term follow-up of survivors of aSAH supports this view [11].

2. Admission policy and selection of patients for treatment

Patients with cerebral aneurysms in Helsinki (350 patients per year, total experience of 7500 patients since 1951) have no admission bias, as all the patients living in Southern Finland (population of 2 million) are admitted to our service. With our increasing experience and loss of experience in some other centers, due to endovascular surgery, patients are also referred to us from other centers in Finland and other countries.

We have to treat all patients regardless of their clinical grade or morphology of the aneurysm, and we give many high-risk patients a chance to recover. Despite all improvements in imaging, microsurgical and endovascular techniques, and intensive care and rehabilitation, still half of the patients with aSAH succumb all over the world.

Those patients who survive the initial bleed for at least a few hours still have a management mortality of 20% to 35%, even when treated with great experience and using the most sophisticated methods. Depending on the selection of patients for open or endovascular surgery, the surgical mortality can be 1% to 25%, even higher in complex aneurysms especially in elderly patients [13,19]. As a rule, if the pupils of the patients are reactive, we advocate immediate surgery. Naturally, patients with expanding significant hematomas are operated on immediately, including clipping of the aneurysm, as are young patients with dilated pupils if not of long endurance. Nearly half (45%) of all patients are operated on within 24 hours, 78% within 72 hours. Notably, poor-grade patients have no delay and are consequently treated during the first day [1,2,13,19].

While waiting for the therapy of choice (clipping or coiling), the risk for rebleeding can be reduced by intravenous administration of tranexamic acid 1 g 4 times a day for 4 days or until surgery [3], but rebleeding can still happen despite this, and in the high flow of patients it has happened many times with fatal outcome.

2.1. Preoperative management

Before surgery or coiling, systolic arterial blood pressure is controlled, and blood pressures above 160 mm Hg are treated with labetalol. Low blood pressures not likely to

ensure adequate cerebral perfusion pressure are treated as well; it is noteworthy that after SAH the autoregulation curve is shifted to the right, and seemingly, an adequate perfusion pressure does not guarantee sufficient cerebral blood flow [4]. In our practice, in most cases, phenylephrine is the drug of choice. However, SAH may lead to myocardial insufficiency, and the addition of dopamine or the combination of noradrenaline and dobutamine may be necessary to achieve hemodynamic stability. If the latter are needed, the monitoring of cardiac output and systemic vascular resistance are recommended to determine the correct infusion rates of the potent vasoactive drugs. Nimodipine is frequently used in patients with SAH, but it can be especially dangerous in elderly patients.

In patients with aSAH and/or space-occupying hematomas, a higher blood pressure can be allowed to secure adequate perfusion pressure. After the skull is opened and the hematoma is partially evacuated, the high arterial pressure is quickly returned to the normal level. The transmural pressure of the aneurysm sac is one of the determinants of the risk of rebleeding, and as it cannot be measured individually, the accepted blood pressure remains at the discretion of the physician [9].

In conscious patients, headache can be relieved by administering small doses of opioids, our preference is intravenous oxycodone in 2-mg increments and 500 mg to 1 g acetaminophen either orally or intravenously. In most patients, small doses of anxiolytic drugs (diazepam) can be beneficial; however, the combination of midazolam and an opioid should be administered cautiously because of the pronounced respiratory depressing effect [12]. Nausea and vomiting should be prevented; our drug of choice is granisetron 1 mg intravenously because the most potent drug for this purpose, DHPB, is too sedative. The sedative effects of drugs can be harmful by masking possible after sudden neurologic deterioration.

In conscious patients, observation without invasive monitoring is acceptable, but in patients with GCS 8 or less, an endotracheal tube and controlled ventilation are needed, together with invasive monitoring of the hemodynamics. Of course we lose the possibility of grading the neurologic status, but we feel it is more important to save lives than to grade exactly (cf Yasargil's grade U = unknown). Laryngoscopy and intubation cause a stress response with increase in blood pressure; therefore, sufficient anesthesia is required before intubation to prevent rebleeding. When ventilation is controlled, sedation with propofol is considered.

Nimodipine therapy is often initiated immediately after the confirmation of aneurysmatic SAH. It can be administered either by a continuous infusion or orally, 60 mg 6 times a day. To prevent transient hypotension after nimodipine administration, 10 mg of etilefrine is given orally at the same time with the nimodipine tablets. If nimodipine is administered intravenously, phenylephrine infusion is often needed to maintain normo- or hypertension postoperatively (see below).

Preoperatively, a CT scan is performed to confirm the SAH diagnosis, and at our department it is immediately followed by CTA, which gives noninvasively and very quickly (only in a few minutes) the location and morphology of the aneurysm. Usually, the patients are admitted directly from CT scan into the OR while the 3-dimensional images are processed with more details for the neurosurgeon. We can begin the operation even within 30 minutes after diagnosis is made.

The patients are not allowed to eat or drink unless conservative treatment is chosen. Intravenous infusion with Ringer's solution made isotonic with the addition of sodium (100–200 mL/h) is continued until surgery or intravascular treatment. Other electrolytes can be added as needed, but glucose should not be given during the first 3 days of the hemorrhage. Diuresis exceeding the normal amount an hour is substituted with Ringer's solution or a hypotonic saline solution, depending on the plasma concentration of sodium. Diabetes insipidus is not uncommon especially in patients with anterior communicating artery aneurysm.

3. Neuroanesthesia in microsurgery of aneurysms

3.1. Induction of anesthesia

The induction of anesthesia should be smooth to prevent rebleeding at this time, and it is smooth, as we have not experienced any rebleedings during the induction in the past 10 years. All patients have an intravenous line already on admission in the OR, and it can be used for the administering of induction drugs. The insertion of an arterial cannula is recommended before the induction of anesthesia to monitor and treat any sudden changes in arterial blood pressure—any change, an increase or a decrease in the transmural pressure of the aneurysm sac, can lead to rupture.

Before the induction of anesthesia we recommend glycopyrrolate 0.2 mg intravenously. Thereafter, fentanyl, in a dose sufficient to prevent the hemodynamic response to laryngoscopy and intubation, is given (5–7 $\mu\text{g}/\text{kg}$) [18]. For

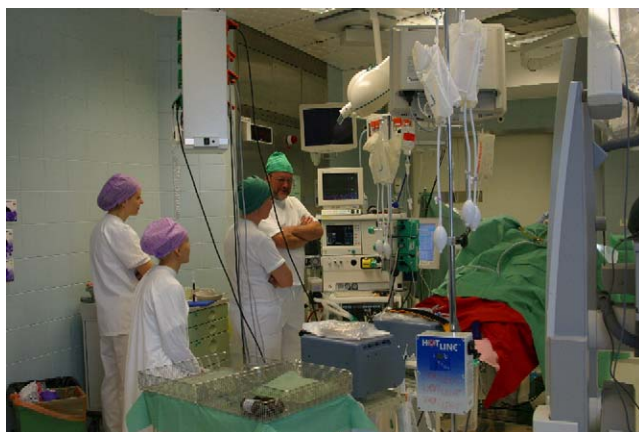

Fig. 2. General view of the anesthesia working station.

the induction, we prefer a sleep dose of thiopentone, but propofol can also be chosen [21]. If propofol is chosen, a small intravenous bolus of lidocaine is injected to prevent pain caused by the induction drug [24]. The choice of the muscle relaxant is at the discretion of the anesthesiologist (Figs. 1 and 2).

3.2. Maintenance of anesthesia

In patients with mild symptoms and only minor SAH without intracranial or intraventricular hematoma, anesthesia can be maintained with isoflurane or sevoflurane in oxygen and nitrous oxide or air. With sevoflurane or isoflurane, the depth of anesthesia should not exceed 1 MAC with or without nitrous oxide, and the inspiratory concentration of sevoflurane must not exceed 3% because of the assumed epileptogenic effect [7]. In patients with severe SAH, often associated with an ICH/IVH and clinical evidence of increased ICP, propofol is the drug of choice for the maintenance of anesthesia [16]. In addition, if there is brain edema, the administration of any inhalation anesthetic including nitrous oxide must be discontinued, and anesthesia should be maintained with propofol.

Fentanyl in 0.1-mg boluses or an infusion of remifentanyl is recommended for analgesia. It is notable that remifentanyl has a marked hypotensive effect, and it can be

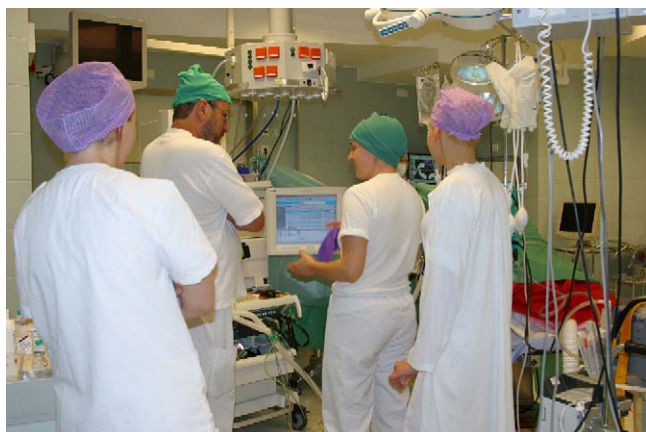

Fig. 1. The neuroanesthesia team: senior anesthesiologist discussing the case with the resident and the anesthesia nurse.

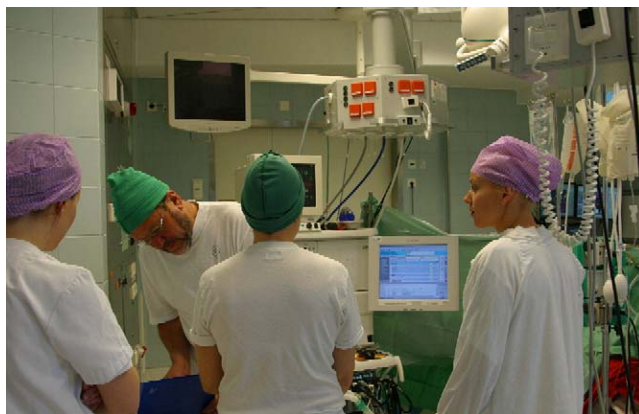

Fig. 3. Automatic anesthesia data collection.

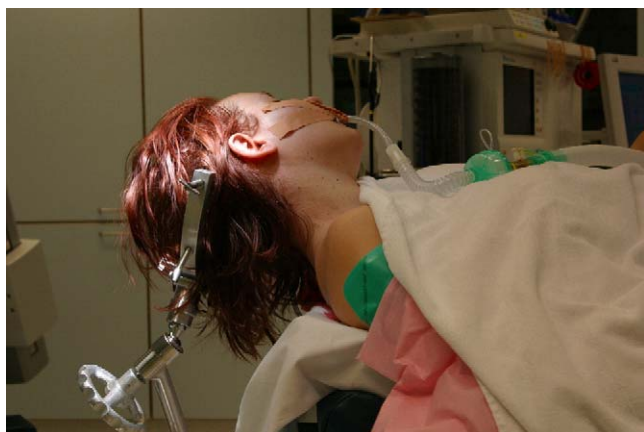

Fig. 4. Positioning of patient head high above the heart.

given in 0.05- to 0.15-mg boluses to control hypertension or to prevent sudden increases of arterial blood pressure as a response to painful stimuli, such as the application of the pins of the head holder. Fentanyl is preferred in patients who are likely to need controlled ventilation postoperatively, and remifentanyl in those who will be awakened after surgery. The first 1-g bolus of acetaminophen should be infused well before the end of surgery. NSAIDs including COX-2 selective drugs are not recommended during the acute phase [14]. Muscle relaxants are again at the discretion of the anesthesiologist (Fig. 3).

In patients with SAH, we infuse 500 mL of 15% mannitol, or 1 g/kg, before the start of surgery. Other diuretics are not considered necessary at this point. In poor-grade patients with red and angry swollen brain and those with an ICH or IVH, propofol is the essential drug of choice for the maintenance of anesthesia [9,16].

The patient's head is positioned 20 cm or even more above the heart level (Fig. 4) to reduce venous bleeding in the operative field, and the neck is in a neutral position to ensure free venous return. Head position is tailored according to aneurysm location, direction, and morphology (Fig. 5). The head is fixed with a Sugita frame by the senior neurosurgeon in our service; we do not administer local

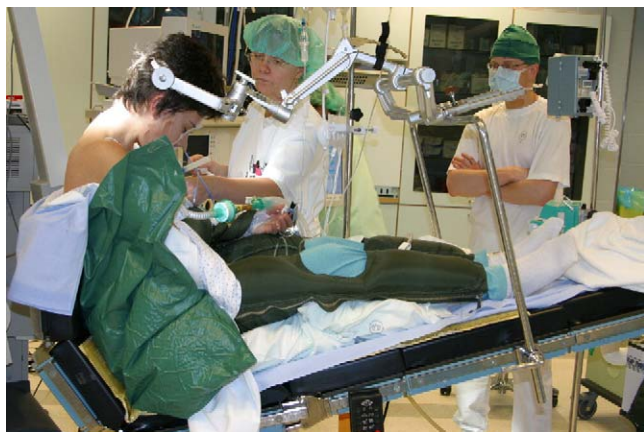

Fig. 5. Senior anesthesiologist supervising the positioning of the patient.

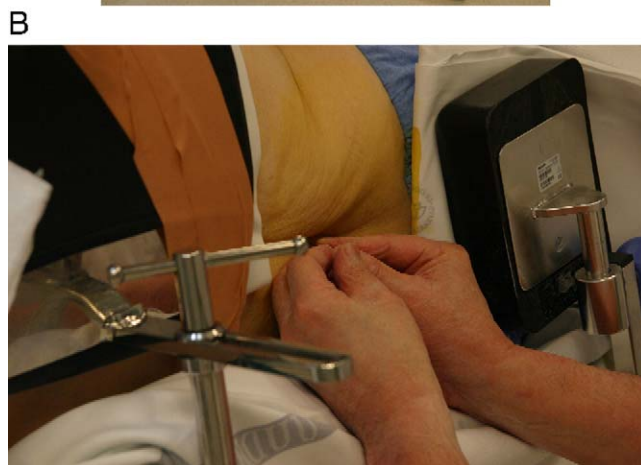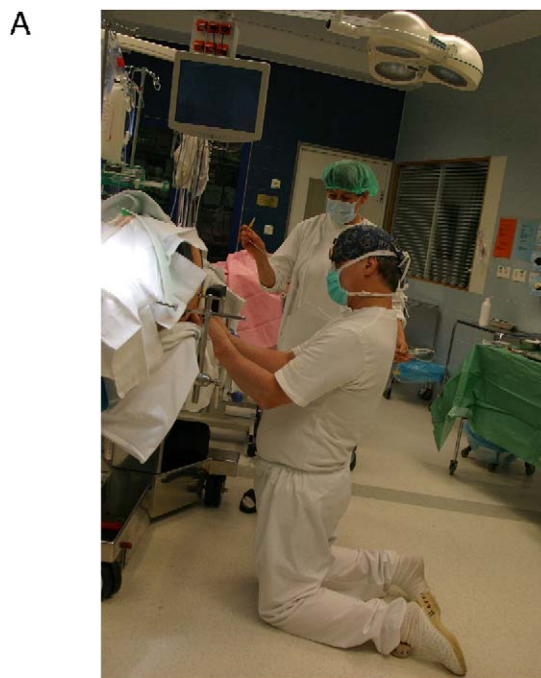


Fig. 6. A and B: Professor of neurosurgery (JH) inserting spinal drainage, which is a must in posterior circulation aneurysm surgery.

anesthetics for the pin fixation but instead give an extra bolus of remifentanyl in advance to avoid elevation of blood pressure. It is also our routine to apply spinal drainage to remove CSF preoperatively in posterior circulation aneurysms (Fig. 6A and B).

Ventilation is adjusted to achieve normoventilation or mild hyperventilation to keep PCO_2 at 4.5. to 5.0 kPa. All inhalational anesthetics are discontinued if the brain is tight at the time of opening the skull, and anesthesia is maintained with propofol.

As previously mentioned, neurogenic pulmonary edema, if present (and nowadays is an indication for ultracarly surgery), often subsides when the skull is opened and CSF is released through the lamina terminalis and/or the expanding hematoma is removed. However, the reason remains unclear, but it can be related to decreased lower limit of

the perfusion pressure, which is needed to ensure adequate cerebral blood flow.

The base of the aneurysm is nowadays easily measured preoperatively in DSA or CT angiography very accurately, and this measurement helps to select the smallest possible clips to occlude the base of the aneurysm without any special instrument (the length of the clip should be 1.5 times the width of base measured in angiography). It is our policy not only to clip the aneurysm but also to “kill” it by opening the sac, followed by coagulation.

3.3. Preoperative aneurysm rupture

Premature aneurysm rupture alarms the team. Often the bleeding can be controlled with suction and by placing a temporary clip that occludes the feeding artery.

We have used a short cardiac arrest induced by adenosine to control the bleeding from the ruptured aneurysm in fewer than 10 patients so far [15]. Adenosine is an antiarrhythmic drug that effects the sinoatrial conduction, and is normally used for the treatment of tachyarrhythmias. To induce cardiac arrest, 12 mg of adenosine is injected as a rapid bolus in a large vein, and it is followed by approximately 10-second arrest. During this short period, the operative field is suctioned, and a temporary clip(s) or a so-called pilot clip is placed. Normal rhythm returns without any need for medical intervention. However, controlled studies are needed to validate this intervention, and it must be kept in mind that because of the properties of the drug, administration of adenosine may be followed by bradycardia instead of transient arrest. An experienced neurosurgeon can see from the anatomy of the aneurysms which are prone to rupture prematurely and have the adenosine ready beforehand.

3.4. Anesthesia during temporary clipping

Temporary clipping is used increasingly to improve the surgical conditions. A well-planned strategy can prevent searching for clips and losing valuable time. Depending on the duration of the temporary occlusion of a cerebral artery, protective measures are needed. When the expected duration is less than 60 to 120 seconds, there is no need for interventions, but if the duration is likely to be longer, the following interventions are made:

1. The inspiratory concentration of oxygen is increased to 100%.
2. Barbiturate (thiopental) is administered as an intravenous bolus dose up of to 1 g to reduce metabolism and oxygen consumption, and at the same time the patient is given phenylephrine in 25- to 100- μ g increments to prevent hypotension.
3. Additional doses of phenylephrine may seldom be given to increase the arterial blood pressure at least 20% above baseline to ensure retrograde circulation to the areas distal to the temporary clip, as it may induce cumbersome bleeding at the operative area, prolonging and making the temporary clipping adjustment and removal more difficult, even dan-

gerous. Postoperative controlled ventilation and sedation are often necessary when the duration of temporary clipping exceeds 5 to 10 minutes.

In selected cases with an anticipated duration of temporary clipping of 10 minutes or more, induction of mild to moderate hypothermia is considered, bearing in mind the discouraging results of the IHAST study [22]. Intraoperative angiography has recently caused changes in the clip application in many cases.

3.5. Termination of anesthesia

The need for postoperative controlled ventilation and sedation is discussed in each case separately. Patients with only mild symptoms after SAH, minimal brain swelling during surgery, and only a short duration of temporary clipping can usually be awakened and the endotracheal tube can be removed at the operating table.

After the discontinuation of anesthetics, including the infusion of remifentanyl, the arterial blood pressure must be controlled with 10- to 20-mg boluses of labetalol. Any sudden increases in arterial blood pressure carry a risk for intracranial bleeding. When remifentanyl is used to provide preoperative analgesia, a 6-mg intramuscular injection of oxycodone is given approximately 15 to 20 minutes before planned extubation.

The endotracheal tube cannot be removed until the patient is awake and obeys commands. If the awakening time is prolonged beyond the expected elimination time of the effects of the anesthetic drugs, a CT scan should be considered to rule out a postoperative hematoma or other causes of unconsciousness. Before extubation, the end-tidal concentration of carbon dioxide should not be allowed to rise—in case of a postoperative hematoma, even mild hypercarbia can cause a marked increase in the ICP.

3.6. Fluid therapy

Glucose-containing fluids are not given during the first 3 days unless the patient is hypoglycemic. The desired level of blood glucose is 4 to 6 mmol/L, and to achieve this, short-acting insulin is administered either as needed or as a continuous infusion containing insulin 1 IU/mL.

Adult patients are infused with Ringer's acetate made isotonic with additional sodium, 100 to 125 mL/h, or to maintain normovolemia or the central venous pressure at 6 to 12 mm Hg. The fluid loss caused by mannitol infusion and surgical bleeding are restored by isotonic fluids and blood products if needed. After surgery, we do not aim at hyper- or hypovolemia, but normovolemia with isotonic or slightly hypertonic fluids. Magnesium sulfate (10 to 20 mmol) is added to the first 1000 mL of Ringer's acetate.

3.7. Monitoring

In all patients with SAH, an arterial line is inserted immediately for continuous monitoring of arterial blood pressure and for obtaining blood samples. Electrocardiogra-

phy is monitored continuously during surgery and at the NICU. Arterial saturation of oxygen is monitored by pulse oximetry. Central venous line is not necessary preoperatively or during surgery, but if vasoactive drugs or an intravenous infusion of nimodipine is needed, one is inserted postoperatively. In addition, it is necessary in poor-grade patients or in those with vasospasm or having any electrolyte imbalance. During surgery, and in patients who require controlled ventilation, the end tidal concentration of carbon dioxide is monitored. Arterial partial pressure of carbon dioxide is analyzed at 1-hour intervals during surgery and at 6-hour intervals postoperatively. Naturally, a urinary catheter is mandatory if the patient is administered mannitol. In addition, in patients with SAH, urinary output monitoring may be helpful in maintaining the desired volume status. In patients with high ICP or SAH from the anterior communicating artery, diabetes insipidus occurs frequently.

Usually, in patients with severe SAH, the lamina terminalis is opened and a catheter is left inside the third ventricle; the other end is tunneled subcutaneously and used for ICP monitoring and release of CSF if necessary (rise of ICP > 15 H₂O cm, drainage at the level of 10 H₂O cm).

In patients with suspected or diagnosed vasospasm, a cardiac output monitor is often required to guide the administration of vasoactive drugs. In our clinic, we use the Picco monitor™ (PULSION Medical Systems AG, Munich, Germany), which gives information of cardiac performance and systemic vascular resistance.

3.8. Postoperative care

Patients with only mild to moderate symptoms after SAH and short duration of temporary clipping do not usually require postoperative controlled ventilation, but their tracheas can be extubated at the operating table as soon as the patients are awake.

In all patients, 1 g acetaminophen is given as an intravenous infusion 3 to 4 times daily for analgesia and to prevent and treat hyperthermia. Analgesia is supplemented with intravenous oxycodone 2 to 3 mg as needed. Anxiety is treated with benzodiazepine or haloperidol. The maximum dose of haloperidol is limited to 15 mg a day because of the QT disturbances often seen in the ECGs of the patients with SAH. In patients requiring controlled ventilation, propofol infusion is started for sedation. Our patients are not given prophylactic antiepileptic medication routinely except for cases with temporal or frontal hematomas.

Apart from the general care, special attention is paid to the prevention and treatment of arterial vasospasm, with the greatest risk for up to 14 days after the bleed. The risk of vasospasm is evaluated individually. All patients are admitted to the NICU postoperatively, and the duration of their stay depends on the above-mentioned risk for delayed cerebral ischemia. Those patients with minimal bleeding and good grade do not usually need prolonged NICU care.

All patients are kept normo- or mildly hypervolemic by infusion with 3000 to 4000 mL of Ringer's acetate with

added sodium (20 to 40 mmol/L). In patients with a low risk for vasospasm, systolic arterial pressure is kept at or above 110 mm Hg; in the medium-risk patients, above 130 to 140 mm Hg; and in the high-risk patients, above 140 to 160 mm Hg. To prevent transient hypotension after oral administration of nimodipine, the patients are administered etilefrine 10 to 20 mg orally at the same time the patient is given the nimodipine tablets. The preferred vasoactive drugs are phenylephrine and dopamine if needed, but if the target pressures are not achieved with reasonable doses of these drugs, infusions of noradrenaline and dobutamine can be started.

The serum electrolyte balance is monitored carefully, and hyponatremia is considered a sign of imminent postoperative complications. Hyponatremia can be a result of SIADH or cerebral salt wasting syndrome and can occur in the same patient interchangeably [20]. For the former, the treatment is fluid restriction, but for the latter case, the urinary loss is corrected with sodium-containing fluids.

Percutaneous tracheotomy is done in poor-grade patients on the third to seventh day if a prolonged recovery is to be expected.

In conclusion, SAH is a devastating disease affecting other organs beyond the brain. The aim of the therapy is to prevent rebleeding by careful preoperative treatment and by either clipping or coiling the aneurysm. Perioperative treatment and the lengths of stay in the NICU are evaluated individually, although certain standard operation practices are applicable. Vasospasm causes further morbidity and mortality in patients with SAH.

References

- [1] Hernesniemi JA. Mechanisms to improve treatment standards in neurosurgery, cerebral aneurysm surgery as example. *Acta Neurochir Suppl* 2001;78:127-1934.
- [2] Hernesniemi J, Niemelä M, Karatas A, et al. Some collected principles of microneurosurgery: Simple, fast and preserve normal anatomy. A review. *Surg Neurol* 2005;64:195-200.
- [3] Hillman J, Fridriksson S, Nilsson O, et al. Immediate administration of tranexamic acid and reduced incidence of early rebleeding after aneurysmal subarachnoid hemorrhage: a prospective randomized study. *J Neurosurg* 2002;97:771-8.
- [4] Joshi S, Ornstein E, Young W. Cerebral and spinal cord blood flow. In: Cotrell JE, Smith DS, editors. *Anesthesia and neurosurgery*. 4th ed. Mosby: St Louis; 2001. p. 19-68.
- [5] Juvela S, Siironen J, Kuhmonen J. Hyperglycemia, excess weight, and history of hypertension as risk factors for poor outcome and cerebral infarction after aneurysmal subarachnoid hemorrhage. *J Neurosurg* 2005;102:998-1003.
- [6] Kotapka MJ, Flamm ES. Cerebral aneurysms: surgical considerations. In: Cotrell JE, Smith DS, editors. *Anesthesia and neurosurgery*. 4th ed. Mosby: St Louis; 2001. p. 353-65.
- [7] Kurita N, Kawaguchi M, Hoshida T, et al. The effects of sevoflurane and hyperventilation on electrocorticogram spike activity in patients with refractory epilepsy. *Anesth Analg* 2005;101:517-23.
- [8] Kurokawa Y, Uede T, Ishiguro M, et al. Pathogenesis of hyponatremia following subarachnoid hemorrhage due to ruptured cerebral aneurysm. *Surg Neurol* 1996;46:500-7.

- [9] Lam A. Cerebral aneurysms: anesthetic considerations. In: Cotrell JE, Smith DS, editors. *Anesthesia and neurosurgery*. 4th ed. Mosby: St Louis; 2001. p. 367-96.
- [10] Macmillan CS, Grant IS, Andrews PJ. Pulmonary and cardiac sequelae of subarachnoid haemorrhage: time for active management? *Intensive Care Med* 2002;28(8):1012-23.
- [11] Manninen PH, Gelb AW. The anesthetic management of patients during posterior fossa aneurysm surgery. In: Drake CG, Peerless SJ, Hernesniemi JA, editors. *Surgery of vertebrobasilar aneurysms*. London, Ontario experience on 1767 patients. Springer-Verlag: Vienna; 1996. p. 280-4.
- [12] Murray MJ, DeRuyter ML, Harrison BA. Opioids and benzodiazepines. *Crit Care Clin* 1995;11:849-73.
- [13] Niemelä M, Koivisto T, Kivipelto L, et al. Microsurgical clipping of cerebral aneurysms after the ISAT study. *Acta Neurochir Suppl* 2005;94:3-6.
- [14] Niemi T, Tanskanen P, Taxell C, et al. Effects of nonsteroidal anti-inflammatory drugs on hemostasis in patients with aneurysmal subarachnoid hemorrhage. *J Neurosurg Anesthesiol* 1999;11:188-94.
- [15] Nussbaum ES, Sebring LA, Ostanny I, et al. Transient cardiac standstill induced by adenosine in the management of intraoperative aneurysmal rupture: technical case report. *Neurosurgery* 2000;47:240-3.
- [16] Petersen KD, Landsfeldt U, Cold GE, et al. ICP is lower during propofol anaesthesia compared to isoflurane and sevoflurane. *Acta Neurochir Suppl* 2002;81:89-91.
- [17] Randell T, Tanskanen P, Scheinin M, et al. QT dispersion after subarachnoid hemorrhage. *J Neurosurg Anesthesiol* 1999;11:163-6.
- [18] Randell T. Haemodynamic responses to intubation: what more do we have to know? *Acta Anaesthesiol Scand* 2004;48:393-5.
- [19] Ronkainen A, Niskanen M, Rinne J, et al. Evidence for excess long-term mortality after treated subarachnoid hemorrhage. *Stroke* 2001;32:2850-3.
- [20] Sherlock M, O'sullivan E, Agha A, et al. The incidence and pathophysiology of hyponatraemia after subarachnoid haemorrhage. *Clin Endocrinol (Oxf)* 2006;64:250-4.
- [21] Tanskanen PE, Kytta JV, Randell TT. QT interval and QT dispersion during the induction of anaesthesia in patients with subarachnoid haemorrhage: a comparison of thiopental and propofol. *Eur J Anaesthesiol* 2002;19:749-54.
- [22] Todd MM, Hindman BJ, Clarke WR, et al. Intraoperative Hypothermia for Aneurysm Surgery Trial (IHSA) Investigators. Mild intraoperative hypothermia during surgery for intracranial aneurysm. *N Engl J Med* 2005;352(2):135-45.
- [23] van den Bergh WM, Algra A, Rinkel GJ. Electrocardiographic abnormalities and serum magnesium in patients with subarachnoid hemorrhage. *Stroke* 2004;35:644-8.
- [24] Yew WS, Chong SY, Tan KH, et al. The effects of intravenous lidocaine on pain during injection of medium- and long-chain triglyceride propofol emulsions. *Anesth Analg* 2005;100:1693-5.

Commentary

The authors provide a clinically oriented review of issues that are important to anesthesia providers caring for patients with aSAH. The emphasis on the multisystem sequelae of aSAH is valuable. The practical clinical recommendations provided will interest anesthesia providers with limited and substantial experience in caring for patients undergoing treatment for cerebral aneurysms. Although the authors' practice largely mirrors ours at the University of California, Los Angeles, and presumably many North American centers, where it diverges provides us with the welcome opportunity to reconsider our own practice.

Barbara Margaret Van de Wiele, MD
Department of Anesthesiology
UCLA, Los Angeles, CA 90095, USA